

Aus der Klinik für Nephrologie und Rheumatologie
(Prof. Dr. med. M. Zeisberg)
der Medizinischen Fakultät der Universität Göttingen

Characterization of the eye phenotype in children with Alport syndrome

INAUGURAL-DISSERTATION

zur Erlangung des Doktorgrades
der Medizinischen Fakultät der
Georg-August-Universität zu Göttingen

vorgelegt von

Clara Berenice Juliane Großmann

aus

Berlin

Göttingen 2021

Dekan: Prof. Dr. med. W. Brück

Betreuungsausschuss

Betreuer/in: Prof. Dr. med. O. Gross

Ko-Betreuer/in: Prof. Dr. med. N. Feltgen

Prüfungskommission

Referent/in: Prof. Dr. med. O. Gross

Ko-Referent/in:

Drittreferent/in:

Datum der mündlichen Prüfung:

Hiermit erkläre ich, die Dissertation mit dem Titel "Characterization of the eye phenotype in children with Alport syndrome" eigenständig angefertigt und keine anderen als die von mir angegebenen Quellen und Hilfsmittel verwendet zu haben.

Göttingen, den

.....
(Unterschrift)

Table of contents

List of figures	III
List of tables	IV
List of abbreviations	V
1 Introduction	1
1.1 Definition and epidemiology of Alport syndrome	2
1.2 Pathogenesis of Alport syndrome.....	3
1.3 Genetics.....	4
1.3.1 Genotype-phenotype correlation	5
1.4 Clinical manifestation	6
1.4.1 Nephrological symptoms.....	6
1.4.2 Ocular symptoms.....	8
1.4.3 Auricular symptoms	9
1.5 Diagnosis.....	10
1.6 Therapy.....	12
1.6.1 ACE inhibitors	13
1.6.2 Dialysis.....	15
1.6.3 Kidney transplantation.....	15
1.6.4 Future potential therapy options	16
1.6.5 Therapy surveillance.....	17
1.7 Objectives.....	17
2 Material and Methods	18
2.1 EARLY PRO-TECT Alport Trial	18
2.2 Patient collective	19
2.3 Data collection	19
2.4 Statistical methods	20
3 Results	21
3.1 Evaluation of the patient collective.....	21
3.1.1 Age of patients and examinations	21
3.2 Ocular findings.....	22
3.2.1 Ocular changes.....	22
3.2.2 Astigmatism and refractive power.....	25
3.2.3 Stages of Alport syndrome, severity of the variants, and the kidney progress.....	28
3.2.4 Correlation of ocular and renal parameters	29
4 Discussion	32
4.1 Summary of main results	32
4.2 Discussion of results	32

4.2.1	Astigmatism	32
4.2.2	Myopia	35
4.2.3	Hyperopia.....	35
4.2.4	Macular thinning	36
4.2.5	Macular pigment	38
4.2.6	Further macular findings	40
4.2.7	Vitreous body degeneration	41
4.2.8	Additional ocular changes found in other studies	42
4.2.9	Variant	45
4.2.10	Limitations of the study	46
4.2.11	Discussion conclusion.....	46
4.3	Outlook	48
5	Summary	49
6	Appendix.....	50
6.1	Worksheet	50
6.2	Alport eye pass	51
6.3	Alport eye pass in German.....	52
7	References	53

List of figures

Figure 1 Mode of inheritance	21
Figure 2 Pathologic ocular changes in total	22
Figure 3 Alport specific and nonspecific ocular changes	23
Figure 4 Patients with Alport specific ocular changes	23
Figure 5 Age at examination period finding an Alport specific ocular change	24
Figure 6 Prevalence of astigmatism in EPA patients	26
Figure 7 Distribution of children with refractive power.....	26
Figure 8 Percentage of patients with Alport stages 0, I, and II	28
Figure 9 Relation between refractive power and Alport stages	30
Figure 10 Severity of the variant in patients with astigmatism.....	31
Figure 11 Patients with temporal macular or retinal thinning in cited studies with related examination methods	38
Figure 12 Number of patients with lenticonus in cited studies with related examination methods.....	43
Figure 13 Patients with retinopathy in cited studies with related examination methods.....	45

List of tables

Table 1 Stages and clinical manifestations of AS.....	7
Table 2 Age at first inspection.....	21
Table 3 Age at last inspection.....	22
Table 4 Number of medical reports.....	22
Table 5 Alport nonspecific ocular changes found in the EPA patients	24
Table 6 Refractive power classification by age at the time of examination	27
Table 7 Relation between astigmatism and refractive power.....	28
Table 8 Inheritance and severity of the variant	29
Table 9 Refractive power and severity of the variant	29
Table 10 Astigmatism in EPA Alport patients compared to astigmatism in healthy patients of cited studies.....	34
Table 11 Macular pigment, kidney status, and examination methods in cited studies	40
Table 12 Comparison of examination methods in the EPA trial and cited studies.....	47

List of abbreviations

ACE	Angiotensin converting enzyme
ACEi	Angiotensin converting enzyme inhibitor
ADAS	Autosomal dominant Alport syndrome
ARAS	Autosomal recessive Alport syndrome
AS	Alport syndrome
AT	Angiotensin
CKD	Chronic kidney disease
Crea	Creatinine
EPA	EARLY PRO-TECT Alport
ESKD	End stage kidney disease
FSGS	Focal segmental glomerulosclerosis
GBM	Glomerular basement membrane
GFR	Glomerular filtration rate
N/A	Not applicable
OCT	Optical coherence tomography
RAAS	Renin angiotensin aldosterone system
RAASi	Renin angiotensin aldosterone system inhibitor
SEM	Standard error of the mean
SGLT2	Sodium-glucose cotransporter 2
STD	Standard deviation
TGF	Transforming growth factor
XLAS	X-linked Alport syndrome

1 Introduction

Alport syndrome (AS) is a hereditary disease with a triad of symptoms consisting of a progressive loss of kidney function, sensorineural hearing loss, and ocular defects (Gross et al. 2012a). Terminal renal insufficiency is often present at an early adult age, resulting in the need of treatment with dialysis (Gross 2017).

AS can be treated if it is diagnosed and treated early (Savige et al. 2013; Gross 2017). The progress of renal dysfunction can be delayed by starting a therapy with angiotensin converting enzyme inhibitors (ACEi) (Torra and Furlano 2019). Gross et al. performed mice experiments in 2003, demonstrating that early therapy with the ACEi ramipril delays the onset of renal insufficiency and renal fibrosis. Register data showed that treatments with ACEi delayed the time to dialysis for patients treated with ACEi compared to non-treated Alport patients (Gross et al. 2012a). In a further study conducted on the basis of a register data in 2009, the assumption was confirmed that ACEi could also reduce renal fibrosis and the occurrence of proteinuria in humans (Gross et al. 2012a). There was a significant difference regarding the patient age when terminal renal failure occurred between initiation of therapy with ACEi in comparison to no therapy (Gross et al. 2012a). So far, there is no curative therapy for AS (Torra and Furlano 2019). The aim of existing therapies with nephroprotective drugs is to delay the progression of the disease (Nozu et al. 2019).

This dissertation is based on the EARLY PRO-TECT Alport (EPA) trial. The EPA trial is the first randomized prospective placebo-controlled trial to evaluate the risk-benefit ratio of an early ACEi therapy in oligosymptomatic children with AS (Gross et al. 2012b). From 2012 to 2019 the EPA trial examined the relevance of treating children with the ACEi. Primary endpoints were safety and efficacy of early treatment with ACEi in children with AS (Gross et al. 2012b). The EPA trial results showed that pre-emptive ramipril therapy slows early disease progression and is safe (Gross et al. 2020).

The objective of this dissertation is to characterize the eye phenotype in children with AS. This dissertation examines the ocular reports collected within the EPA trial. The impact of AS on the eyes and the relation of the symptomatology between the kidney and the eyes is examined. This is done in respect to the background that AS can cause significant eye damage to the eyes of pediatric patients.

1.1 Definition and epidemiology of Alport syndrome

AS is a hereditary progressive kidney disease, characterized by changes in the glomerular basement membrane (GBM) (Kashtan and Michael 1996). The patients present hematuria, proteinuria, and progressive renal failure (Gross et al. 2012a). AS is the second most common cause of inherited terminal kidney failure after the polycystic kidney disease (Grünfeld and Joly 1997). Extrarenal symptoms include sensorineural hearing loss and characteristic ocular defects (Alport 1927). These findings were first described in 1927 by the English physician Arthur C. Alport.

A defect collagen type IV (see 1.2 Pathogenesis of AS) leads to a splitting of the GBM, resulting in inflammation, glomerulosclerosis, and fibrosis (Gross et al. 2012a). In addition to fibrosis, the accumulation of extracellular matrix and podocyte effacement lead to a loss of the kidney function (Funk et al. 2018). Eventually, patients develop end stage kidney disease (ESKD), which leads to dialysis or kidney transplantation (Kruegel et al. 2013).

AS is a genetic disorder, occurring in 1:5000 people with XLAS and in 1:50 000 people with autosomal AS (Levy and Feingold 2000). It is responsible for over 1% of the population receiving dialysis or kidney transplantation and accounts for up to 4% of all patients with ESKD (Gross et al. 2017; 2020). There is no known curative treatment for AS (Torra and Furlano 2019). The disease will inevitably lead to ESKD during early adulthood in X-chromosomal and autosomal linked inheritance modes (Torra and Furlano 2019). About 50% of untreated AS patients develop ESKD by the age of 20 years (Gross et al. 2012a). Almost 1% of the population is a carrier of heterozygous variants in the COL4A3/4 genes (Gross et al. 2002).

1.2 Pathogenesis of Alport syndrome

AS is a complex dysfunction of basement membranes characterized by the expression of distinct type IV isoforms of collagen (Kashtan and Michael 1996). Basement membranes separate different tissues from one another in the body. They surround epithelia, endothelia, peripheral nerves, muscle, and fat cells. They influence cell metabolism, cell differentiation, cell migration, and cell polarity (Weber 1992). The GBM is surrounded by podocytes and fenestrated glomerular endothelium in the glomerulus of the kidney (Funk et al. 2018). It serves to ultrafiltrate the blood plasma and builds the filtration barrier of the kidney, forming a membrane between blood and urine (Funk et al. 2018). The GBM consists of various proteins such as laminin, heparan sulfate proteoglycan, nidogen and, as mentioned above, type IV collagen (Funk et al. 2018).

Type IV collagen is indispensable for the body, forming a main component of all basal membranes. It is an essential part of the GBM and the filtration barrier of the kidney (Pöschl et al. 2004). Type IV collagen forms a network in the GBM that ensures stability and a high flexibility of the kidney (Gross and Weber 2005).

The pathophysiology of AS is based on changes in the GBM (Watson and Bush 2018). These changes are caused by variants in three genes that code for type IV collagen: COL4A3, COL4A4, and COL4A5 (Kruegel et al. 2013). The variants lead to structural and functional defects in type IV collagen molecules and therefore in the GBM networks (Kruegel et al. 2013). They are responsible for the loss of function of the kidney filtration barrier and the resulting glomerulopathy (Kruegel et al. 2013).

The type IV collagen family comprises six α chains, $\alpha 1$ to $\alpha 6$ (Kruegel et al. 2013). These six chains assemble into three different triple helices, also called heterotrimers: $\alpha 1\alpha 1\alpha 2$, $\alpha 3\alpha 4\alpha 5$, and $\alpha 5\alpha 5\alpha 6$ (Kruegel et al. 2013). The superhelices consist of approximately 1400 glycine-X-Y repeats which are interrupted by several non-collagenous domains (Boutaud et al. 2000). Each type IV collagen α chain consists of a non-collagenous domain (NC1) at the carboxy-terminal end, a central collagenous domain of glycine-X-Y repeats, and a short amino-terminal non-collagenous 7S domain. By combining the carboxyterminal NC1 domains, three type IV collagen α chains each form heterotrimers. Type IV collagen trimers combine with each other through carboxy- and amino-terminal interactions and thus form the networks of the basement membranes (Boutaud et al. 2000). While the $\alpha 1$ and $\alpha 2$ chains are ubiquitously found in basement membranes, the $\alpha 3$, $\alpha 4$, $\alpha 5$, and $\alpha 6$ chains show organ-specific distributions (Hudson et al. 2003). The $\alpha 3$, $\alpha 4$, and $\alpha 5$ chains are present in the GBM of the kidney. The $\alpha 5$ chain can also be found in the Bowman capsule of the kidney (Kashtan and Michael 1996). The $\alpha 3$, $\alpha 4$, and $\alpha 5$ chains can be found in the anterior lens capsule, the Descemet's membrane, the Bruch's membrane, and in the inner limiting membrane in the eye (Kashtan 2000). In the ear, these chains can also be found in several membranes of the cochlea such as the basilar membrane, the basement membranes of the stria vascularis, spiral limbus, and spiral prominence (Kashtan and Michael 1996; Kashtan 2000).

The basic defect in AS, due to variants in the mentioned genes, is either the lack of the $\alpha3\alpha4\alpha5$ heterotrimer in the GBM and its failure to replace the $\alpha1\alpha2$ network or the presence of a defective $\alpha3\alpha4\alpha5$ heterotrimer (Heidet and Gubler 2009). Normally, the $\alpha3$ and $\alpha4$ chains form trimers with the $\alpha5$ chains to be built into the basement membranes (Kashtan 2003). In COL4A5 variants such as deletions or frameshift variants, no or only a shortened $\alpha5$ chain is formed (Kashtan 2003). Variants which shorten the α chain can result in an onset of ESKD at an average age of 20 years and increase the prevalence of extrarenal symptoms (Gross 2004). The heterotrimers consisting of $\alpha3$, $\alpha4$, and $\alpha5$ chains can no longer form, and none of the three α chains occurs in the basement membrane. Variants in the $\alpha3$ and $\alpha4$ chains can have similar consequences (Kashtan 2003). If the connection of the $\alpha3\alpha4\alpha5$ network does not occur, only $\alpha1$ and $\alpha2$ chains are installed, which are not able to form a mature GBM. Networks of $\alpha3\alpha4\alpha5$ chains have different capabilities than $\alpha1$ and $\alpha2$ chains (Kashtan 2000). The $\alpha3\alpha4\alpha5$ chains perform functions in the GBM, ocular basement membranes, and cochlear basement membranes which cannot be performed by $\alpha1$ and $\alpha2$ chains (Kashtan 2000). The defect network results in a splitting of the GBM which leads to decreased mechanical stability (Kruegel et al. 2013). Podocyte loss takes place due to the presence of the premature type IV collagen heterotrimer $\alpha1\alpha1\alpha2$ (Kruegel et al. 2013). Furthermore, podocyte detachment from the GBM leads to glomerulosclerosis and later on fibrosis (Kruegel et al. 2013; Funk et al. 2018). A consequence of this defect network may be the lenticonus anterior. Some patients with lenticonus anterior show no presence of a $\alpha3\alpha4\alpha5$ network, resulting in a thinning of the anterior lens capsule (Kashtan and Michael 1996).

1.3 Genetics

Phenotypically, a heterogeneous appearance can be observed (Kruegel et al. 2013). Patients therefore differ in the occurrence of typical AS symptoms (Rheault et al. 2019). Not all patients suffer from inner ear hearing loss and ocular changes in addition to kidney involvement (Wester et al. 1995). There are three genetic types of AS: X-linked Alport syndrome (XLAS), autosomal recessive Alport syndrome (ARAS), and autosomal dominant Alport syndrome (ADAS) (Heidet and Gubler 2009). Making up 85% of the cases, XLAS is the most common inherited form and is caused by variants in the COL4A5 gene (Heidet and Gubler 2009). The gene COL4A5 is located on the X chromosome (Xq22.3) (Kashtan 2004). In about 15% of the cases, the disease is inherited autosomal and is linked to variants in the genes COL4A3 or COL4A4 (Kashtan 2003).

The majority of patients affected by the XLAS hereditary pathway consists of female patients. Male patients with XLAS all develop terminal kidney failure (Kashtan 2003). 75% of men with XLAS suffer from the juvenile form, developing ESKD before the age of 30. In the other 25% of cases, terminal renal failure occurs after the age of 30 (adult form) (Renieri et al. 1996). Female patients with XLAS usually show a more benign course than men (Jais et al. 2000). Most patients with XLAS have a positive family history of hematuria (Kashtan

2009). However, in 10-15% of the XLAS cases, de novo variants are involved, so there may be a negative family history (Kashtan 2009).

AS in its autosomal form can be transferred from both parents to son or daughter. In contrast to the X-chromosomal inheritance, autosomal inheritance allows fathers to pass AS on to their sons (Gross 2004). In patients with autosomal inheritance, the clinical course of the disease is the same in men and women. The clinical appearance and course of the autosomal recessive pathway are similar to those of the X-linked pathway (Kashtan 1999). Truncating variants lead to renal failure at 20 years of age, whereas glycine-missense variants lead to kidney failure at 30 years of age (Gross et al. 2002).

A very rare form leading to 5% of AS is the autosomal dominant inheritance form (Kashtan 2003). It is due to variants in COL4A3 or COL4A4, which manifests less aggressively than XLAS and ARAS (Kashtan 2018). In 10-15 % of AS patients, there might be no family history of kidney disease. Here, possible causes can be de novo variants and germ line variants of the mother (Gross 2004).

1.3.1 Genotype-phenotype correlation

A genotype-phenotype correlation in AS was described in studies from Jais et al. and Gross et al. (Jais et al. 2000; Gross et al. 2002). More than 300 variants in the COL4A5 gene are known (Netzer et al. 1993). The type of variant can predict the patient age of reaching ESKD (Gross et al. 2002). Variants can be classified into moderate, moderate severe, and severe. This can be adopted to the variant classification in the EPA trial of mild, moderate, and severe. The moderate variant includes glycine XY variants. Patients with this variant are likely to develop ESKD at 30 years of age and will develop ocular symptoms in up to 30% of the cases. Moderate-severe variants involve non-glycine XY missense variants, in frame, and acceptor splice site variants. This genotype leads to ESKD at an average of 26 years and patients can experience ocular symptoms in up to 30% of the cases. The severe variant is characterized by large rearrangements, deletions, stop, frameshift, and donor splice site variants, leading to an ESKD already at 20 years of age and to ocular symptoms in up to 40% of the cases (Gross et al. 2002). In summary, it can be said that the studies of Gross et al, Jais et al., and Savige et al. showed that severe variants lead to an ESKD at an earlier age and are more likely to also affect the eyes and ears (Jais et al. 2000; Gross et al. 2002; Savige et al. 2016).

Studies have demonstrated the correlation between severe COL4A5 variants and ocular features (Jais et al. 2000). 40% of male patients with XLAS have characteristic ocular changes (Jais et al. 2000). 20% of XLAS male patients and 15% of female patients exhibit maculopathy (Jais et al. 2003). Another 20% of male patients demonstrate lenticonus anterior, rarely observed in female patients. Patients with large COL4A5 variants have a higher chance of lenticonus and ESKD (Jais et al. 2000). Patients with ARAS can show similar ocular changes as XLAS patients (see 1.4.2 Ocular symptoms)(Colville et al. 1997).

Patients with a severe variant rather than a moderate variant showed ocular changes such as a dot and fleck retinopathy, lenticonus, and a perimacular retinopathy (Tan et al. 2010). Another study found that seven polymorphisms of COL4A3 and COL4A4 could be associated with a lenticonus (Štabuc-Šilih et al. 2009). The theory, which is an important aspect for genetic testing (see 1.5 Diagnosis), is that the PAX6 gene is present in renal and ocular tissue. PAX6 plays a role in the structural regulation of the cornea. Therefore, a variant in this gene may be linked to a keratoconus and renal disease (Bahar et al. 2010).

Certain ocular features may be linked to a X-chromosomal or an autosomal mode of inheritance (Kashtan 2001). A peripheral retinopathy in the mother of a boy with hematuria can help to identify an X-chromosomal linked AS. Common ocular changes in AS such as the anterior lenticonus and central retinopathy, have been connected to an autosomal inheritance mode caused by nonsense variants (Jais et al. 2000).

Deafness develops in 80% of male AS patients with XLAS (Jais et al. 2000). In ARAS this percentage is reached by male and female patients. Approximately 50% of male patients with COL4A5 variants experience deafness by the age of 25 and 90% are deaf by 40 (see 1.4.3 Auricular symptoms) (Jais et al. 2000).

1.4 Clinical manifestation

1.4.1 Nephrological symptoms

The clinical nephrological manifestation of AS shows a broad spectrum of symptoms, ranging from isolated microhematuria to terminal kidney failure (Torra and Furlano 2019). AS is a progressive kidney disease that causes a gradual decline in the kidney function (Funk et al. 2018). It eventually leads to renal insufficiency and finally ESKD in young adult patients at an average age of 22 when left untreated (Gross et al. 2012a).

Due to the loss in kidney function, the kidney cannot eliminate toxic substances and excess fluid from the body which leads to proteinuria, edema, and increased blood pressure (Gross et al. 2012a; Funk et al. 2018).

Typical renal symptoms of AS are hematuria, proteinuria, and albuminuria; hematuria being the cardinal symptom (Kashtan and Michael 1996). AS can be classified into stages 0-IV (Gross et al. 2012b). The table below summarizes the five stages of AS with the correlating symptoms (Gross et al. 2012b). The symptoms increase from stage 0 to stage IV.

Table 1 Stages and clinical manifestations of AS (Gross et al. 2012b)

Stage	Nephrological symptoms
0	Microhematuria without microalbuminuria
I	Microalbuminuria: 30-300 mg albumin/g Crea
II	Proteinuria: > 300 mg albumin/gCrea
III	>25% decline of normal renal function /decrease of normal GFR < 60 ml/min/1.73 m ² . Fibrosis
IV	ESKD

Stage 0 includes the first and most common symptom of AS: persistent microhematuria without microalbuminuria (Gross et al. 2012b). Persistent microhematuria is found in all boys from birth who exhibit an X-chromosomal linked inheritance (Kashtan 2003). If boys do not have microhematuria in the first ten years of their life, they are unlikely to have AS (Kashtan 2003). Girls who are heterozygous carriers of X-chromosomal linked and autosomal AS develop intermittent hematuria in up to 98% of the cases (Yamamura et al. 2017). Up to 5-10% of these patients never develop hematuria (Kashtan 2003). Episodes of hematuria can occur after upper respiratory tract infections in the first two decades of life (Kashtan and Michael 1996).

Stage I includes microalbuminuria of 30-300 mg albumin/g creatinine.

Proteinuria of more than 300 mg albumin/g creatinine manifests as a subsequent symptom in stage II of AS (Gross et al. 2012b). It occurs once the disease has progressed. It is usually not yet present in childhood years (Kashtan 2003). Proteinuria eventually develops in all male patients with an XLAS and in both men and women with an autosomal AS (Kashtan 2003).

Stage III includes patients who have developed a decreased renal function with a GFR under 60 ml/min/1.73 m² (Kruegel et al. 2013).

The last stage of AS and chronic kidney disease (CKD) is ESKD (Gross et al. 2012b). ESKD is reached once the GFR decreases below 15 ml/min/1.73 m² and is often accompanied by uremia (Braun 2018). In this stage patients require dialysis or renal transplantation to stay alive. The time of occurrence of terminal renal insufficiency depends on the mode of inheritance and the gene variant of the patient (see 1.3 Genetics) (Kashtan 2018).

1.4.2 Ocular symptoms

Ocular changes in AS include lenticonus anterior, central and peripheral retinopathy, maculopathy, and corneal erosions (Savige et al. 2010). Ocular changes are common for AS; they occur in 30-40% of patients with XLAS (Jais et al. 2000). They manifest similarly in ARAS patients (Colville et al. 1997).

Lenticonus anterior is pathognomonic in AS patients, it occurs in about 20% of male patients with XLAS (Jais et al. 2000). More recent studies have even detected lenticonus in 50% of male XLAS patients (Savige et al. 2015). Being pathognomonic, lenticonus anterior can be used to confirm the diagnosis of AS (Kruegel et al. 2013). It is more common in men but can also occur in female patients (Kashtan 2003). Lenticonus anterior is defined as a protrusion of the central anterior lens surface into the lens capsule (Ohkubo et al. 2003). Due to the absence of the $\alpha3\alpha4\alpha5$ network in the capsule, the lens can protrude through the thinned and weakened capsule (Ohkubo et al. 2003). The capsule may rupture in areas of weakness, resulting in cataracts near the anterior and posterior poles (Sonarkhan et al. 2014).

Lenticonus is associated with early-onset renal failure and deafness (Jais et al. 2000; Gross et al. 2002; Tan et al. 2010). Lenticonus occurs much more frequently in patients with large COL4A5 deletions or variants that alter the reading frame (Jais et al. 2000; Gross et al. 2002; Tan et al. 2010). In about 75% of the cases, lenticonus appears bilateral (Kashtan 2003). It is absent at birth and becomes present in the second and third decade of life in early middle ages after the onset of renal failure (Kashtan 2003; Savige et al. 2015). Lenticonus anterior can impair the vision—patients cannot focus and may experience blurred vision because of the abnormal shape of the lens (Savige et al. 2015). This cannot be corrected with refraction but only with a surgical lens replacement (Savige et al. 2010; Ravi Kant Bamotra 2017).

60% of male AS patients and at least 15% of female patients with XLAS and 50% of patients with ARAS, exhibit central retinopathy (Savige et al. 2015). Almost all patients with central retinopathy also express peripheral retinopathy (Savige et al. 2015). Central retinopathy manifests as dispersed white and yellow dots and flecks in the temporal macula (Savige et al. 2010; Savige et al. 2015). The macula is the area of the sharpest vision in the retina (Lang 2014). These abnormal pigmentary changes in the retina are also called “dot and fleck retinopathy” (Watson and Bush 2018). In severe cases, densely packed dots form a perimacular ring in the area of temporal retinal thinning (Savige et al. 2015). Central retinopathy progresses with time and is usually first diagnosed at 14 years of age (Tan et al. 2010). The vision is not affected, thus requiring no treatment (Savige et al. 2015). It is best detected with color photographs and redfree images of the macula (see 1.5 Diagnosis) (Savige et al. 2015). Central retinopathy is linked to lenticonus and hearing loss and appears in patients with early-onset renal failure (Shaw et al. 2007; Savige et al. 2015).

Peripheral retinopathy occurs in most male XLAS patients, in 25% of female patients with XLAS, and in the majority of patients with ARAS (Shaw et al. 2007). It is more common than central retinopathy, due to the larger surface area of the periphery (Savige et al. 2015).

Asymmetric flecks and diffuse areas of depigmentation in the retina can be noticed with retinal photography (Shaw et al. 2007; Savige et al. 2015). Similar to central retinopathy, peripheral retinopathy can be noticed in adolescence and progresses until middle age (Shaw et al. 2007). Peripheral retinopathy is linked to lenticonus, early-onset renal failure, and central retinopathy (Savige et al. 2010). It also does not influence vision and therefore does not need to be treated (Shaw et al. 2007).

The dot and fleck retinopathy is another type of retinopathy typical for AS. This is usually defined by splotchy hyperautofluorescent lesions in the perimacular region of the retina (Cho et al. 2017). A reason for this could be the production of an abnormal form of $\alpha 5$ type IV collagen (Gehrs et al. 1995).

Maculopathies such as temporal macular thinning and macular pigment can occur in Alport patients and are important in the diagnosis of AS. Maculopathy is often linked to XLAS or ARAS. In a study, maculopathy could be found in 14% of male XLAS patients and in 15% of female patients with XLAS (Jais et al. 2000). Macular thinning can be detected with optical coherence tomography (OCT) by measuring the thickness of the retina (Ahmed et al. 2013). Temporal thinning can also be seen with retinal color photography (Savige et al. 2015). It appears as a dull macular reflex or lozenge with an oval shaped reflex instead of a normal round small reflex. It does not affect the vision (Savige et al. 2015). Macular pigment usually appears as bright, white or yellow granulations in the area of the macula (Perrin et al. 1980; Gubler et al. 1981; Govan 1983).

An occurrence of vitreous body degeneration can be observed in Alport patients (Shaikh et al. 2003). Studies indicate that the change in structure of the collagen at the vitreoretinal surface may lead to a different adherence, possibly leading to a retinal detachment (Shaikh et al. 2003).

1.4.3 Auricular symptoms

The main auricular symptom of Alport patients is the development of high-tone sensorineural hearing loss. This affects up to 80% of AS patients (Jais et al. 2003).

AS is the most well-known syndrome in which patients have a close relation with clinical kidney and ear manifestations (Phelan and Rheault 2018). Approximately 80% of male and 45% of female AS patients develop sensorineural hearing loss, which is present in the frequency range of 2000-8000Hz (Jais et al. 2000). Hearing loss of AS patients is not congenital, therefore newborn screening is normal (Phelan und Rheault 2018). It becomes apparent in late childhood and young adolescence by audiometry (Kashtan and Michael 1996; Kashtan 2003). 50% of male AS patients with a X-chromosomal linked inheritance develop hearing loss by the age of 15 and 90% by the age of 40 (Jais et al. 2000). Hearing loss progresses over time and can extend to other frequencies and affect conversational speech (Kashtan 2003). Women with an X-linked chromosomal AS are not affected as heavily as men (Kashtan 2003). In comparison to the X-linked chromosomal inheritance there is no

difference in hearing loss in men and women with an autosomal inheritance (Kashtan and Michael 1996). A hearing loss progress up to complete deafness is rare (Harvey et al. 2001). The loss of the $\alpha3\alpha4\alpha5$ network from basement membranes of the cochlea could be a reason for deafness (Kalluri et al. 1998). Research suggests that membranes of the cochlea, type IV collagen in the inner ear, show structural changes in Alport patients, resulting in a stimulation decrease of hair cells (Phelan and Rheault 2018). A study conducted in 2012 demonstrated that the presence of the variant MYH9 with the interaction of COL4A5 can be an explanation for a female patient who expressed hearing loss symptoms at an extremely early age (Strasser et al. 2012). Although the exact mechanism remains unknown, deafness is a prognostic factor for ESKD. Patients with hearing loss are more likely to develop kidney failure (Jais et al. 2003). To conclude, hearing loss affects the majority of AS patients. Additionally, psychosocial aspects such as depression and career dissatisfaction, should not be ignored (Gross et al. 2017).

1.5 Diagnosis

An accurate and early diagnosis of AS is of great importance for the prognosis of the disease (Gross 2017). Typically it is commonly identified late, at a young adolescent age between 10 and 25 years of age when the kidney function is already reduced with a decreased GFR, hematuria, and proteinuria, with many years lying between the first symptoms and the time of diagnosis (Stock et al. 2015; Gross and Rascher 2019).

Diagnostic criteria for AS include: hematuria, proteinuria, a positive family history for hematuria or chronic renal insufficiency, sensorineural hearing loss, visual impairment, and structural changes of the GBM (Gross and Weber 2005).

Diagnostic procedures are patients history, physical examination, family history, urine samples, renal biopsy, and genetic testing.

A diagnosis of AS should be suspected if a patient has hematuria and a positive family history for AS or renal failure (Savige et al. 2013). The clinical diagnosis should include: testing the patient and relatives for hematuria, urine analysis, renal function testing, family history, and audiometry, and ocular examinations (Kashtan 2001). Persistent microscopic hematuria is a hallmark symptom of AS and therefore indispensable in the diagnosis of AS (Grünfeld 2000). 100% of male AS patients with XLAS have microhematuria, as approximately 90% of female patients with XLAS, and about 100% of patients with ARAS present themselves with hematuria (see 1.4 Nephrological symptoms) (Kashtan 2001). Approximately 20% of the children who have been examined by pediatric nephrologists for isolated microhematuria are diagnosed with AS (Kashtan 2001).

The second step in the diagnosis of AS is to collect a detailed family history of the patient (Grünfeld 2000; Gross and Rascher 2019). A known kidney dysfunction or hearing impairment of a relative could be a hint for AS (Gross and Rascher 2019). It can be useful

to obtain urine samples of first degree relatives and to check for familial microhematuria (Gross and Rascher 2019). In male and female patients, three urine samples should be taken before stating an absence of hematuria (Kashtan 2001).

Microscopic hematuria in the mother can suggest an X- chromosomal linked disease. In the father it could be linked to an autosomal inheritance (Grünfeld 2000).

Physical examinations with an audiogram and ocular tests should be done to check for extrarenal manifestations (Kashtan 2001). Hearing defects can be slight or non-apparent and should be detected with an audiogram (Grünfeld 2000). Bilateral high frequency sensorineural hearing loss usually becomes measurable in late childhood when children are aged 6 to 10 years (Kashtan 2001).

Physical ocular examinations include a slit-lamp, retinal photography, and an OCT (Savige et al. 2015). The presence of common ocular changes such as lenticonus anterior and peripheral retinopathy, can confirm the diagnosis of AS (see 1.4.2 Ocular symptoms) (Savige et al. 2015). Anterior lenticonus typically manifests in late adolescent years and can be diagnosed with the help of slit-lamp examination to detect corneal dystrophy. The lenticonus can also appear as a bubble in the red reflex or as an oil-droplet sign on direct ophthalmoscopy (Savige et al. 2015). An annular dark shadow separates the bright reflex of the central and peripheral areas due to a reflection of the light (Prajna 2013).

Central and peripheral retinopathies can be diagnosed with an ocular examination and retinal photographs. Central retinopathies are preferably diagnosed with red free images whereas peripheral retinopathy may need retinal photographs extending their view into the periphery. Retinal color photography can also help diagnose retinal temporal thinning. A dull reflex of the macula instead of a normal round foveal reflex is characteristic (see 1.4.2 Ocular symptoms). Another diagnostic method to confirm retinal thinning is to measure the thickness of the retina on an OCT. An OCT is useful in evaluating the retina and occurring abnormalities such as a thinning of the retina and macula, or lamellar holes, as these are not detectable with retinal photographs (Savige et al. 2015).

Lenticonus, central retinopathy, and the dot and fleck retinopathy may indicate an onset of early kidney failure before the age of 30 (Jais et al. 2000; Tan et al. 2010).

These tests are easily available, quick to undertake, inexpensive, and easy accessible to patients (Savige et al. 2015). There are no guidelines specifying what kind of ocular tests should be performed in patients with AS.

A renal biopsy can be performed to confirm a diagnosis of AS (Kashtan 2001). This diagnostic method is recommended in cases where the clinical and family history are not typical or where no relevant variants have been found (Kashtan 2001). Electron microscopy should be performed to examine the GBM (Kruegel et al. 2013). Diffuse thickening and fragmentation of the GBM are typical for the AS (Pirson 1999). Male patients with XLAS typically show an absence of $\alpha 3$, $\alpha 4$, and $\alpha 5$ chains in immunostaining in the biopsy (Kashtan

2001). A renal biopsy can detect other abnormalities such as a focal segmental glomerulosclerosis (FSGS) or an IgA glomerulonephritis (Savige et al. 2019).

The goldstandard for diagnosis of AS is the molecular genetic analysis (Gross and Rascher 2019). It contributes to diagnosing complex pathologic diseases or identifying a misdiagnosed nephropathy (Groopman et al. 2018). Using next generation sequencing, a genetic analysis is recommended by the expert guidelines of 2019 (Savige et al. 2019). The guidelines recommend that patients with suspected AS should be tested for variants in all three Alport genes (COL4A5, COL4A3, and COL4A4) (Savige et al. 2019). The determination of these variants can confirm the diagnosis of AS and the type of inheritance (Savige et al. 2013). Knowing the form of inheritance can help to identify other family members at risk and possible disease reoccurrence (Savige 2018). Genetic testing can replace a renal biopsy in many patients (Gross 2004). It is less invasive than a renal biopsy and has a specificity of 95% (Kashtan 2001). Another advantage of genetic testing is to know the type of variant. It can help to anticipate the clinical course of the disease. The detection of the variant allows an early diagnosis in the stage of isolated hematuria and therefore the possibility of an early begin of treatment (Gross 2004). Families should undergo genetic counseling (Gross 2017).

To summarize: children with persisting microhematuria, especially with a positive family history for hematuria or chronic renal insufficiency, should undergo a genetic diagnostic examination and see a nephrologist every six months (Gross and Rascher 2019). Genetic testing has become the diagnostic test of choice, providing information about the possible severity of the disease and its prognosis (Savige et al. 2019).

1.6 Therapy

Therapy options for AS have been the subject of clinical research for many years. The long course of the disease combined with still unknown pathomechanisms finally leading to kidney failure make it difficult to establish an ideal treatment scheme (Gross 2004). In addition, a chronic degenerative disease with genetic origin is difficult to treat. Yet, much progress has been made in the last 30 years (Rheault et al. 2019). Animal models were used to explore the pathogenesis of the renal disease and to target specific therapeutic approaches (Heidet and Gubler 2009). Until today the aim of existing therapies is to prevent the progression of the disease (Nozu et al. 2019). There is currently no curative therapy available for AS (Torra and Furlano 2019). No therapies are known to protect patients from ocular changes or hearing loss (Kruegel et al. 2013). Available therapies for ocular and auricular manifestations are only visual aids such as glasses and hearing aids. From the age of 7 or 8, patients should be examined yearly with hearing and visual tests (Kashtan et al. 2013). Clinical manifestations of the eyes can only be treated symptomatically, a lenticonus or cataract can be treated with lens removal or replacement (Moshirfar et al. 2019).

Available therapies available are ACEi upon signs of proteinuria and hematuria, dialysis upon reaching ESKD, and renal transplantation as a last option for a better quality of life and a complete healing of the renal symptomology. New therapeutic approaches such as MiR-21 inhibition are currently being investigated (Torra and Furlano 2019).

1.6.1 ACE inhibitors

The ACEi ramipril is the first line therapy recommended for AS (Kashtan et al. 2013). It is the most successful therapy available, reducing blood pressure and proteinuria and can extend the time until dialysis becomes necessary (Gross et al. 2012a).

The angiotensin converting enzyme (ACE) transforms angiotensin I to angiotensin II. This enzyme is an important factor of the renin angiotensin aldosterone system (RAAS) which plays a significant role in the water and electrolyte balance in the body and in the regulation of the blood pressure. The RAAS is an essential component of the targeted area of therapy of AS (Gross 2017). The liver forms angiotensinogen and the kidney releases renin. Renin is an enzyme which converts angiotensinogen to angiotensin I. Angiotensin I is then transformed to angiotensin II by the ACE. Angiotensin II is responsible for an increase in pressure in the glomerular capillaries, for the induction of chemokines and oxygen radicals and for the stimulation of the synthesis of extracellular matrix (Wolf and Ritz 2005; Ruster and Wolf 2006). It interacts with angiotensin receptors (AT1 receptors) located in the blood vessels, leading to a contraction of the blood vessels and therefore a rise in blood pressure. In addition, angiotensin II releases aldosterone from the adrenal cortex. Aldosterone leads to an increased retention of sodium in the kidney. The resorbed sodium withdraws water from the kidney tubule into the body's blood system, resulting in a further increase in blood pressure (Ruster und Wolf 2006). Thus, the inhibition of ACE and the AT1 receptor blockade lead to a lowering of blood pressure (Brenner et al. 2001; Wolf and Ritz 2005).

In 2003, Gross et al. demonstrated in knockout mice that an early therapy at the stage of isolated hematuria with ACEi delays the occurrence of renal insufficiency and renal fibrosis, reduces proteinuria, and prolongs the life span (Gross et al. 2003). Data of the European registry data of Alport patients confirmed the assumption that ACEi can also reduce proteinuria in humans (Gross et al. 2012a). In addition, the ESCAPE study (Effect of Strict blood pressure Control and ACE inhibition on the progression of chronic renal failure in Pediatric patients) conducted 2004 demonstrated that children with both hereditary and acquired kidney diseases showed benefits in a therapy with ramipril. The blood pressure and proteinuria could be reduced (Wühl et al. 2004).

Therapy with ACEi for AS patients has shown that the need for dialysis can be delayed until the patient has reached a higher age (Gross 2017). An early treatment with ACEi in Alport stage II (see 1.4.1 Nephrological symptoms) can delay kidney failure and the need for dialysis by 18 years (Gross et al. 2012a). If therapy is started in stage III the dialysis can only be delayed by three years (Gross 2017). The current recommendation for grown-ups (patients

over 18 years old) with proteinuria over 0.3 g/day is to receive up to 10 mg/m² ramipril a day. Children (patients under 18 years old) with proteinuria over 0.3 g/day should receive a maximum of 6 mg/m² ramipril a day (Gross et al. 2012b). Currently, ACEi are authorized for children eight years and older with hypertension, yet they are not formally approved for children with proteinuria or kidney diseases (Torra and Furlano 2019). As ACEi are still off-label use in children without hypertension, safety is a concern regarding treatment (Gross et al. 2012a). The EPA trial examined the safety and efficacy of ramipril in children aged two to 17 as well as the optimal start of therapy (Gross et al. 2012a; Gross 2017). The results showed that a preemptive therapy is safe and effective (Gross et al. 2020). The risk of the disease progression was reduced by almost 50%. In addition, a decrease in albuminuria and a diminishment of a decline of the GFR was observed. Gross et al. emphasize that early initiation therapy in stages 0 or I can slow renal failure. Gross et al. suggest that the assessment of hematuria in children and young adults should include a genetic screening for Alport variants (Gross et al. 2020).

In 10% of the patients, the ACEi induced accumulation of bradykinin can lead to the side effect of a dry cough (Overlack 1996).

AT1 antagonists and aldosterone inhibition are the second line therapy (Kashtan et al. 2013). In a study, it was demonstrated that AT1 antagonists significantly lowered proteinuria (Webb et al. 2013). Additionally, it can be helpful to follow a healthy lifestyle, such as reducing salt intake, avoiding being overweight and smoking (Gross 2017).

1.6.2 Dialysis

Dialysis presents a therapeutic option once a patient has reached ESKD (Wolf and Ritz 2005).

Absolute indications to start dialysis are: pericarditis, pulmonary edema, refractory hypertension, uremic encephalopathy and/or neuropathy, a tendency to clinically relevant bleeding, nausea, and vomiting due to uremia (Daugirdas et al. 2012).

Approximately 65,000 patients in Germany receive chronic dialysis therapy (Frei 2008). According to the 2008 annual report of the North American Pediatric Renal Trials and Collaborative Studies (NAPRTCS 2008), 1.9% of the all patients that received dialysis were Alport patients (Strasser et al. 2012). Dialysis is a therapeutic option to bridge the time until renal transplantation.

Without ACEi therapy, the average AS patient is 22 years old when he needs to start with dialysis (Gross et al. 2012a). In comparison, an average dialysis patient who does not have AS is 65 years old (Hiramatsu 2007).

The time span between the diagnosis of AS and the beginning of therapy with dialysis depends on various factors which include: mode of inheritance, variation, and previous therapy the patient has received (Kruegel et al. 2013; Gross 2017).

Heterozygote carriers with XLAS or ARAS carrying more “fortunate” variants such as glycine-variants, can profit from an early therapy with renin angiotensin aldosterone system inhibitors (RAASi). These patients can possibly avoid dialysis (Gross 2017).

1.6.3 Kidney transplantation

A kidney transplant is the favored treatment option for patients with ESKD due to AS. (Kashtan 2018). Some patients are more likely to undergo a transplantation than others depending on sex, variant, and genotype (Kashtan 2018). At the age of 25, 50% of male patients with XLAS reach renal insufficiency (Jais et al. 2000). Of all kidney transplanted patients in the United States in 2000, 2.3% had AS (Atkin et al. 1988).

AS patients usually recover very well after a kidney transplantation (Kashtan 2018). The disease does not recur after the transplantation, unless the donor also had AS (Gross and Kashtan 2009). Studies showed that the patient and graft survival rates are similar or even exceed the rates of patients with other renal diseases (Mallett et al. 2014; Gross et al. 2017). As a rare complication noticed mostly within the first year of the transplant, 0.4% of patients develop antibodies, leading to a post-transplant anti-GBM nephritis (Mallett et al. 2014; Kashtan 2018). Patients who exhibit a missense variant in COL4A5 or have an ADAS have a very low risk of getting this post-transplant disease and those who have large gene deletions have a higher chance of getting this complication (Lemmink et al. 1997; Kashtan 2018). In addition, the type of the kidney transplant donor is important and needs to be considered. There is a significant risk to reach ESKD in women with a X-chromosomal linked AS (Jais

et al. 2003). Therefore, they should not be seen as potential candidates for a transplant (Kashtan 2018).

1.6.4 Future potential therapy options

Beyond the nonspecific RAASi therapy as mentioned above, there is no effective therapy available for Alport patients (Torra and Furlano 2019). New therapy options are needed to prevent the progression of AS. Many innovative approaches and studies in animal models are exploring possible therapy options. MiR-21 inhibitors, Bardoxolone, statins, and Paricalcitol are several examples of treatment options that are currently under investigation (Torra and Furlano 2019).

MiR-21 is a small RNA which contributes to fibrosis in many organs including the kidney (Gomez et al. 2015). Studies which examined the impact of miR-21 inhibiting oligonucleotides in COL4A3 mouse models showed a significant reduction of fibrosis and albuminuria (Gomez et al. 2015). Moreover, it improved survival rates of AS mice by over 40% and led to a decrease in glomerulosclerosis, inflammation, and was protective against TGF β 1 induced fibrosis. These results imply that MiR-21 inhibition could be a possible therapeutic option for chronic kidney diseases including AS (Gomez et al. 2015).

The BEACON study demonstrated an improvement in renal function due to Bardoxolone in patients with CKD stage IV and diabetic nephropathy (Chin et al. 2018). Bardoxolone interacts with the NF- κ B signal pathway of activated B-cells and can increase the GFR, also activating anti-inflammatory and antioxidant genes (Kruegel et al. 2013). The BEACON study had to be stopped due to side effects such as heart failure, repatriable to an excess in fluid because of the suppression of endothelin (de Zeeuw et al. 2013). The CARDINAL study is a new study which examines the impact of Bardoxolone for Alport patients (Torra and Furlano 2019).

Statins (HMG-CoA reductase inhibitors) show nephroprotective and antifibrotic effects (Koepke et al. 2007). One study showed that the survival time of COL4A3 mice treated with the HMG-CoA reductase inhibitor, cerivastatin, could be extended by 28% in comparison to mice with no therapy (Koepke et al. 2007). A reduction of proteinuria and uremia was detected, in parallel to reduced renal fibrosis and the reduction of inflammatory cell infiltration (Gross et al. 2014). Statins inhibit the proliferation of mesangial cells in the kidney and the production of the profibrotic cytokine TGF- β 1 (Kim et al. 2000). Statins could be an additional treatment option for patients with AS and hypercholesterolemia to delay renal failure and to prevent cardiovascular events (Gross et al. 2014).

A combination therapy of ACEi with Paricalcitol was done. Paricalcitol is a vitamin D receptive activator. While positive results were achieved in COL4A3 mouse models, there is not enough evidence to validate this treatment to be effective for humans (Torra and Furlano 2019).

Sodium-glucose cotransporter 2 (SGLT2) inhibitors decrease blood pressure and the GFR (Nespoux and Vallon 2018). Beneficial renal effects are a decrease in filtered albumin and a prevention of an aggravation of renal symptoms in diabetic nephropathy (Davidson 2019). Renoprotective factors of SGLT2 inhibitors are under investigation to verify their therapeutic potential for AS (Davidson 2019).

1.6.5 Therapy surveillance

To prevent secondary complications of AS the following measures can be considered. (Kashtan 2001). Patients with corneal erosions may be able to prevent further minor trauma of the eyes by wearing goggles for protection, for example when riding a bicycle. Pediatric patients should undergo an audiologic examination at the age of six every one to two years (Kashtan 2001). Patients who present a type IV nephropathy should continuously see a nephrologist in addition to a general practitioner. Renal functions need to be assessed once proteinuria has developed. Serum creatinine concentration, GFR, and blood pressure levels should be checked regularly. Women carrying an XLAS mode of inheritance need to be examined on a regular basis by a nephrologist for proteinuria and hypertension (Kashtan 2001; Jais et al. 2003).

1.7 Objectives

The objective of this dissertation is to characterize the eye phenotype in children with AS. Based on the EPA trial, ocular reports are to be examined in order to investigate ocular changes such as refractive power, astigmatism, lenticonus, and macular pigment. In addition, kidney parameters are to be evaluated such as the severity of the variant, stages of the disease, and progress in the disease in order to compare the ocular with the renal symptomatology.

Following questions are to be answered:

Do pediatric Alport patients of the EPA trial show ocular changes?

If yes, what type of ocular changes such as refractive power and astigmatism, or pathologies were found?

Are these findings related specifically to AS?

How do ocular changes evolve over a long time period?

Is there a relation between ocular changes and the severity of the kidney disease, taking into account parameters such as the severity of the variant and stages of AS?

How old were the patients when they were diagnosed with ocular changes?

2 Material and Methods

2.1 EARLY PRO-TECT Alport Trial

This dissertation is based on clinical data collected during the EPA trial. All data within this trial was collected under the direction of the University Medicine of Göttingen and Prof. Dr. med. O. Gross. The primary objective of this clinical trial was to examine the safety and efficacy of the early start for therapy with ACEi in oligosymptomatic children with AS. The results showed that an early initiation of ramipril therapy in Alport stages 0 and I is safe and slows early disease progression (Gross et al. 2020).

The trial is a phase III, multi-center, randomized, placebo-controlled, double-blind study in 66 oligosymptomatic pediatric patients with early stages of AS (Gross et al. 2020). Early stages entail an Alport stage 0 or I with microhematuria, microalbuminuria, and a GFR of $> 90 \text{ ml/min/1.73 m}^2$ (Gross 2017). The trial was conducted in Germany and collected data on the progress of affected individuals since 2012. Participating study centers included 14 sites in Germany.

Three different patient groups were investigated in the trial.

Patients in an early stage of the disease (before proteinuria $> 0.3 \text{ g per day}$) and untreated with ramipril were randomized into two groups between ramipril and placebo (Gross et al. 2012b). 22 patients received ramipril or a placebo for over three years. If a kidney progress was observed, the patients were unblinded and treated with ramipril. Patients in stage II of the disease or previously treated with ramipril, in total 44, were open treated with ramipril (Gross et al. 2020). A progression in stage 0 was defined as a threefold increase of albuminuria, a progression in stage I as a twofold increase from baseline albuminuria, and progression in stage II as a twofold increase from baseline albuminuria (Gross et al. 2020). A possible progress of albuminuria was checked every six months with 24-hour urine by a blinded investigator.

Variants in the EPA trial were classified into mild, moderate, and severe. The mild variant includes glycine XY variants. Moderate variants involve non-glycine XY missense variants, in frame, and acceptor splice site variants. The severe variant is characterized by large rearrangements, deletions, stop, frameshift, and donor splice site variants (Gross et al. 2002). In addition to data on the safety of drug therapy and renal function parameters, the trial included data on hearing function, ocular findings, and family history. An ocular progress was defined as any change in the eyes. Alport specific pathologic ocular reports were defined as a lenticonus, macular changes, vitreous body destruction or opacity, and retinopathies. Alport nonspecific pathologic ocular reports were defined as non-healthy manifestations of the eyes such as strabismus or conjunctival irritation.

In 66 patients who were included, the primary points to be examined were "progress of kidney disease" and "safety". This project was approved by the Ethics Commission of the Georg-August-University under the application number 11/6/11.

2.2 Patient collective

The patients had to meet the following criteria of the EARLY PRO-TECT trial to be included in the database: confirmation of AS by biopsy or molecular genetic analysis, age between two and 18 years, AS stages 0 or I, and no treatment with ACEi unless in the open label treatment arm.

Patients with the following criteria were excluded from the trial: contraindications, allergies or intolerances to ramipril, uncertain diagnosis or being a heterozygous carrier, AS stages II, III or IV, psychological conditions, use of drugs or alcohol, pregnancy, and additional chronic diseases such as cardiac or pulmonary disease or liver dysfunction (Gross et al. 2012b).

2.3 Data collection

Ocular data could be used for 46 out of 66 patients. For these 46 patients the study centers provided the medical ocular reports and the distributed including the worksheet for the ophthalmologist. These ocular investigations were part of the regular routine ocular examinations.

The worksheets were provided to the study centers to complete them, according to the Alport specific changes. A template can be found in Appendix 1. Macular pigment, lenticonus, and cataract were inquired. In addition, regular ocular examinations were performed to check the patients for conspicuous ocular changes. Examinations included the following: refraction measurement, a cover test, slit lamp, and long stereo test. The anterior and posterior sections of the eyes were examined.

Medical findings of the patients were collected by professional monitors. The files were analyzed retrospectively. Demographic data such as date of birth, age, sex, inheritance, and family correspondence were examined. The patient age at the first and last examination, severity of the variant (mild-moderate-severe), stages of AS (0-I-II), and the age at the inclusion of the trial were included. It was documented if and how long the patient received ACEi. Furthermore, the renal and ocular progress were to be documented.

The following ocular parameters were considered: refractive power (hyperopia-myopia-emmetropia), astigmatism, execution of Alport specific tests, lenticonus, cataract, macular pigment, and pathologic and Alport nonspecific clinical findings.

After determining the parameters, the data from the returned worksheets were pseudonymized and compiled in an Excel sheet.

2.4 Statistical methods

The Excel table was prepared in the version 16.33 2019. For the statistical evaluation the SAS software version 9.4 software was used. The data was represented by absolute and relative frequencies as well as mean value, median, and standard deviation. Mean and standard deviation for continuous variables (e.g. age) and relative frequencies for variables with nominal scale (without order, e.g. gender), and ordinal scale (with order, e.g. severity of the variant (=genotype)) were used.

The statistical evaluation was supported by Mr. Sebastian Pfeiffer from the Institute for Medical Statistics in Göttingen.

3 Results

3.1 Evaluation of the patient collective

Ocular data was collected from 46 patients out of 66 children that were included in the trial. Out of these 46 patients, 45 (98%) were male and one (2%) was female. The average age of the patients at the time of the trial inclusion was eight years of age (± 4). The youngest patient was two years old and the oldest patient was 17 years old. Out of 46 patients, the mode of inheritance was XLAS in 38 patients (83%) and autosomal in eight patients (17%).

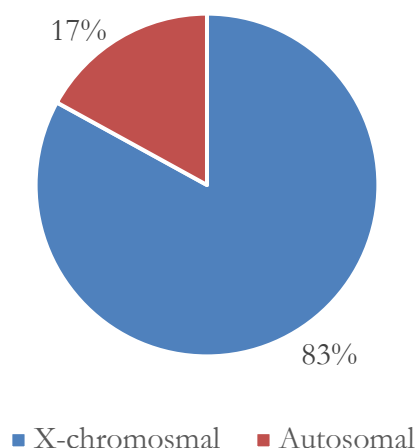


Figure 1 Mode of inheritance, n = 46

3.1.1 Age of patients and examinations

Ideally, patients were to be examined for ocular changes every three years in order to detect an ocular progress. Medical reports were received from 46 out of 66 patients. 21 of these 46 patients had more than one examination.

On average, these 21 patients were nine years old (± 4) when they received the first screening. The youngest patient was one year old and the oldest patient was 15 years old, as shown in Table 2. Patients were on average 13 years old (± 4) at the last screening. The youngest patient was six years old and the oldest patient was 19 years old, as shown in Table 3. The average time span between the first and the last examination was four years (± 2).

Table 2 Age at first inspection

	N	Mean	STD	SEM	Min	Q1	Median	Q3	Max	Mean (95%LCL)	Mean (95%UCL)
Total	21	8.9	4.0	0.9	1.0	7.0	9.0	11.0	15.0	7.1	10.7

Table 3 Age at last inspection

	N	Mean	STD	SEM	Min	Q1	Median	Q3	Max	Mean (95%LCL)	Mean (95%UCL)
Total	21	12.8	4.2	0.9	6.0	10.0	13.0	16.0	19.0	10.9	14.7

As shown in Table 4, 21 of 46 patients had more than one medical report. Eleven patients (24%) had two reports, two patients (4%) had three reports, five patients (11%) had four reports, and three patients (7%) had five reports. 25 patients (54%) only had one report.

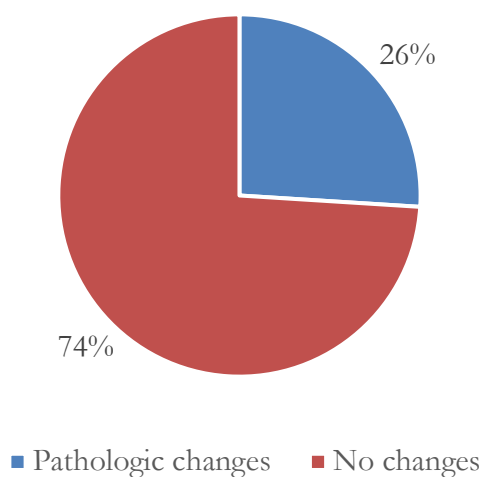
Table 4 Number of medical reports

#	1	2	3	4	5	Total
Total in patients	25 (54.3%)	11 (23.9%)	2 (4.3%)	5 (10.9%)	3 (6.5%)	46 (100%)

3.2 Ocular findings

3.2.1 Ocular changes

Twelve of 46 patients (26%) had pathologic ocular reports, leaving 34 patients (74%) with inconspicuous results.

**Figure 2** Pathologic ocular changes in total, n = 46

Of these twelve patients, five patients (11%) showed Alport specific ocular findings. Seven patients (15%) exhibited Alport unspecific ocular findings, as presented in Figure 3.

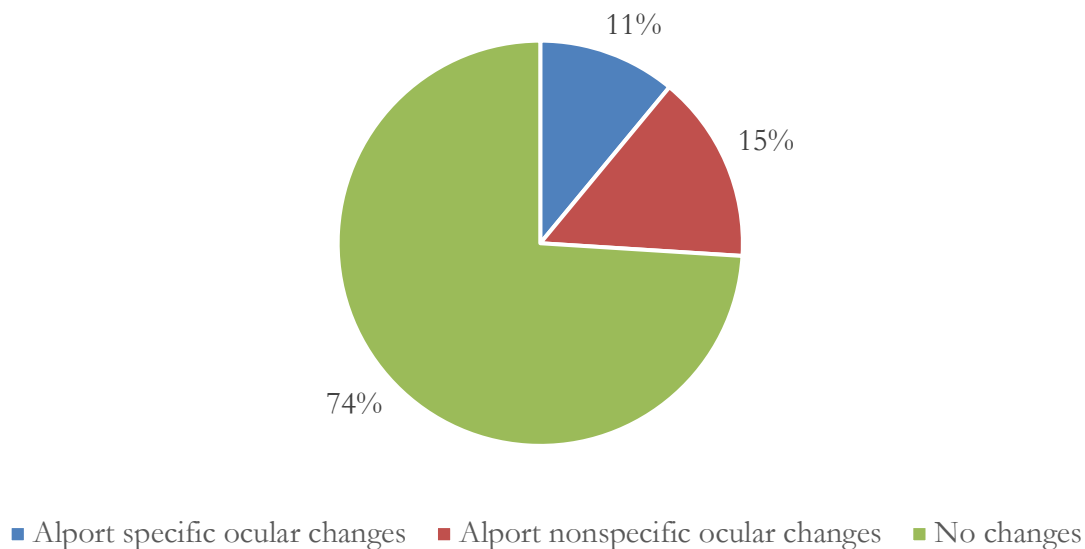


Figure 3 Alport specific and nonspecific ocular changes, n = 46

Out of the five patients with specific AS ocular changes, one patient (2%) exhibited macular pigment, one patient (2%) presented macular thinning, and three patients (7%) showed a vitreous body degeneration.

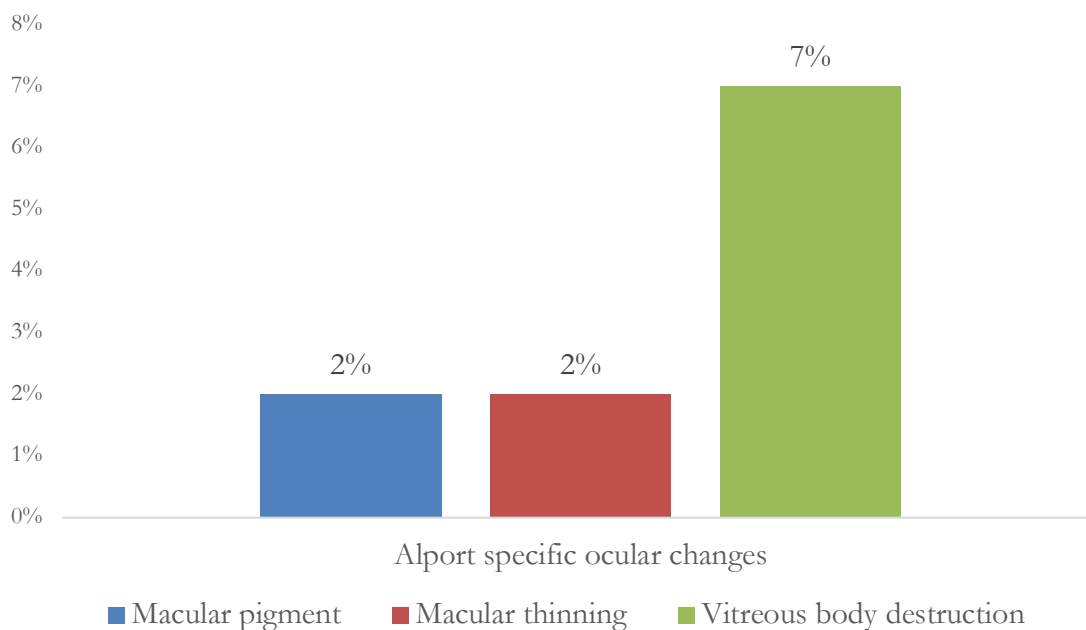


Figure 4 Patients with Alport specific ocular changes, n = 5

The patient who exhibited macular pigment was male with XLAS, 10 years old at the first examination and was examined three times in total, respectively after four years and after two years. He had a variant categorized as moderate, was in Alport stage I, and had a progress of the renal function during the trial. Eyes were emmetropic with no astigmatism.

Macular thinning was diagnosed in a 20 year old man with ARAS in stage II and a variant categorized as moderate with no kidney progress. Hyperopia and astigmatism were verified.

Vitreous body destruction was found in three patients. These were all male and in Alport stage I. Each exhibited an astigmatism. The average age upon diagnosing vitreous body destruction was eight years old, as shown in Figure 5. The first patient was seven years old with ARAS, with a variant categorized as moderate, and hyperopia. No kidney progress was noted. The second patient was eight years old with XLAS, a variant categorized as severe, and emmetropia. The third patient was ten years old with XLAS, and a variant categorized as severe, and emmetropia. No kidney progress was noted.

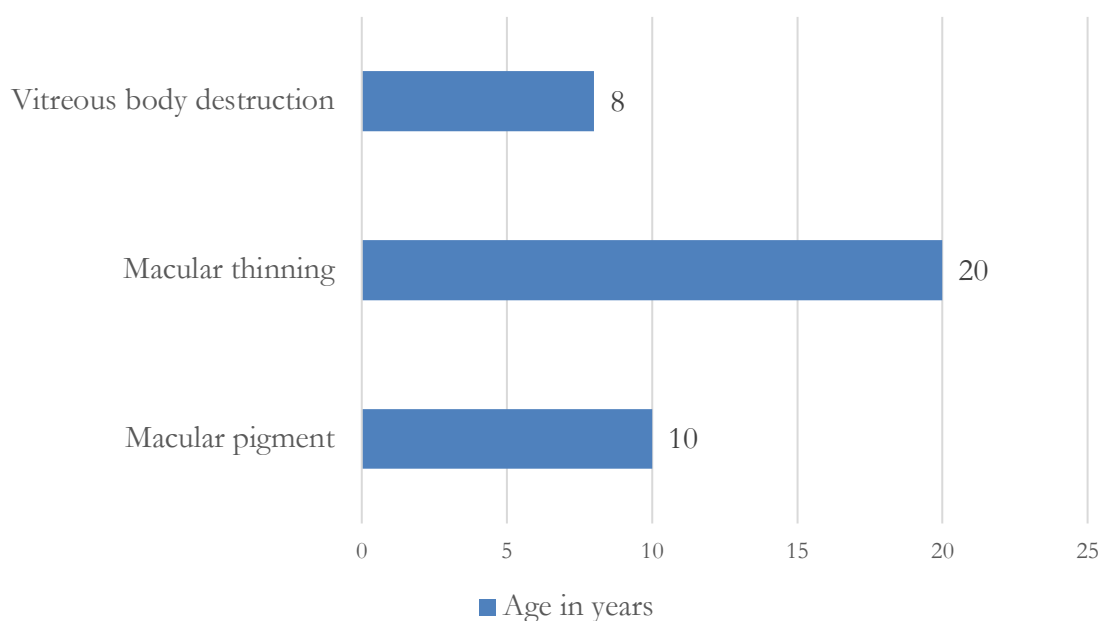


Figure 5 Age at examination period finding an Alport specific ocular change, n = 5

The seven patients (15%) with Alport nonspecific ocular changes are listed below.

Table 5 Alport nonspecific ocular changes found in the EPA patients

Patient-ID	Group	Family-history positive	Severity of the variant	Alport-Stage at trial inclusion	Gender	Year of birth	Year of examination	Age	Findings
93_02_01	Open (R.)	No	Moderate	1	Male	2007	2017	10	Conjunctival irritation
93_03_04	Ramipril	No	Mild	0	Male	1999	2014	15	
	Ramipril	No	Mild	0	Male	1999	2016	17	
	Ramipril	No	Mild	0	Male	1999	2017	18	Blepharitis, Corneal vascularization
	Ramipril	No	Mild	0	Male	1999	2018	19	Corneal vascularization
93_03_05	Placebo	No	Moderate	0	Male	2004	2015	11	Papilla excavation
	Placebo	No	Moderate	0	Male	2004	2018	14	Papilla excavation

Patient-ID	Group	Family-history positive	Severity of the variant	Alport-Stage at trial inclusion	Gender	Year of birth	Year of examination	Age	Findings
93_05_02	Open (R.)	No	Moderate	0	Male	2009	2012	3	Iriscolobom
93_07_03	Open (R.)	No	Moderate	0	Male	2002	2017	15	Short blurred vision
93_12_05	Open (R.)	No	Severe	2	Female	2000	2014	14	Follicular conjunctival swelling on both sides
	Open (R.)	No	Severe	2	Female	2000	2015	15	
	Open (R.)	No	Severe	2	Female	2000	2017	17	
93_13_03	Ramipril	No	Mild	0	Male	1999	2009	10	Inner strabismus, enlarged papilla excavation, borderline retinal nerve layer thickness
	Ramipril	No	Mild	0	Male	1999	2016	17	Inner strabismus

Among these seven patients, ocular medical findings consisted of conjunctival irritation, corneal vascularization, papilla excavation, irisclobom, blurred vision, follicular conjunctival swelling, and inner strabismus. Except one patient at three years old, the age of the patients ranged between ten and 19 years old.

3.2.2 Astigmatism and refractive power

Alport patients were examined for astigmatism and refractive power as part of their regular ocular examinations. An astigmatism was found in over half of the patients, by a total of 24 (52%). One patient (2%) did not have an astigmatism and for 21 patients (46%) no information regarding the astigmatism was included in the medical reports. The average age of the patients at the time of the diagnosis of astigmatism was nine years old (± 4) with a minimum age of one and a maximum age of 20.

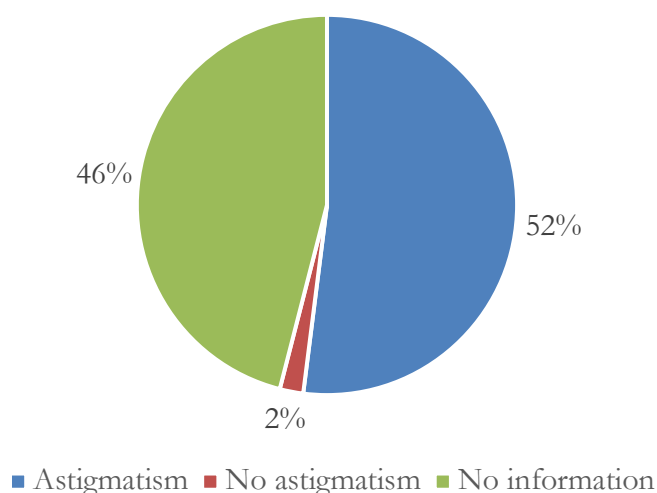


Figure 6 Prevalence of astigmatism in EPA patients, n = 46

Regarding the refractive power, the majority of the patients exhibited hyperopia, including 21 (46%) of the patient collective. Followed by 13 patients (28%) with emmetropia and one patient (2%) with myopia. Eleven patients (24%) did not have information about the refractive power stated in their medical reports.

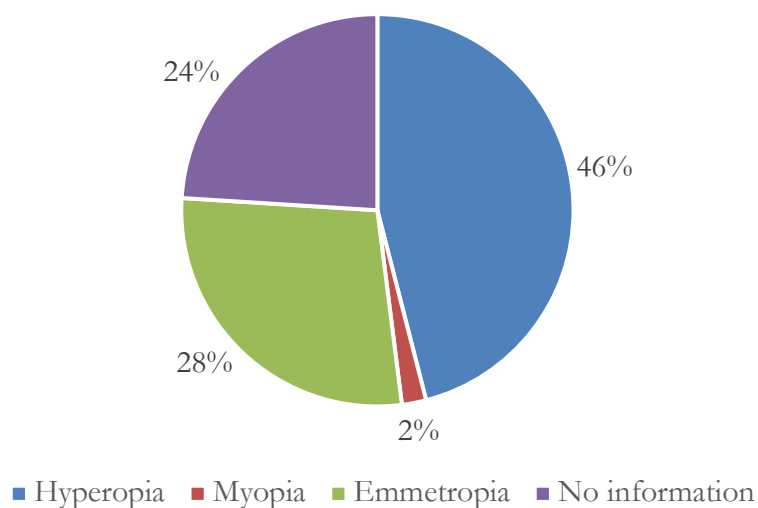


Figure 7 Distribution of children with refractive power, n = 46

The patients were analyzed in regard to their age at the time of examination for the refractive power, as shown in Table 6. Most patients with hyperopia were examined at the age of five, the youngest patient being three years old. The patient with myopia was 14 years old at the time of examination and the majority of patients who exhibited emmetropia were examined at age 13, the youngest being six.

The mean age of patients with hyperopia was 16 years old. The myopic patient was 14 years old at the time of examination and emmetropic patients were 19 years old on average.

Table 6 Refractive power classification by age at the time of examination

Age at the time of the examination	Number of patients with refractive power				Total
	N/A	Myopia	Hyperopia	Emmetropia	
3	1 (25%)	0 (0%)	3 (75%)	0 (0%)	4 (8.7%)
4	1 (50%)	0 (0%)	1 (50%)	0 (0%)	2 (4.3%)
5	1 (50%)	0 (0%)	1 (50%)	0 (0%)	2 (4.3%)
6	3 (75%)	0 (0%)	0 (0%)	1 (25%)	4 (8.7%)
7	0 (0%)	0 (0%)	3 (60%)	2 (40%)	5 (10.9%)
8	0 (0%)	0 (0%)	1 (33.3%)	2 (66.7%)	3 (6.5%)
9	1 (50%)	0 (0%)	1 (50%)	0 (0%)	2 (4.3%)
10	2 (22.2%)	0 (0%)	5 (55.6%)	2 (22.2%)	9 (19.6%)
11	0 (0%)	0 (0%)	1 (33.3%)	2 (66.7%)	3 (6.5%)
13	0 (0%)	0 (0%)	1 (25%)	3 (75%)	4 (8.7%)
14	0 (0%)	1 (50%)	1 (50%)	0 (0%)	2 (4.3%)
15	0 (0%)	0 (0%)	2 (66.7%)	1 (33.3%)	3 (6.5%)
18	1 (100%)	0 (0%)	0 (0%)	0 (0%)	1 (2.2%)
20	1 (50%)	0 (0%)	1 (50%)	0 (0%)	2 (4.3%)
Total	11 (23.9%)	1 (2.2%)	21 (45.7%)	13 (28.3%)	46 (100%)

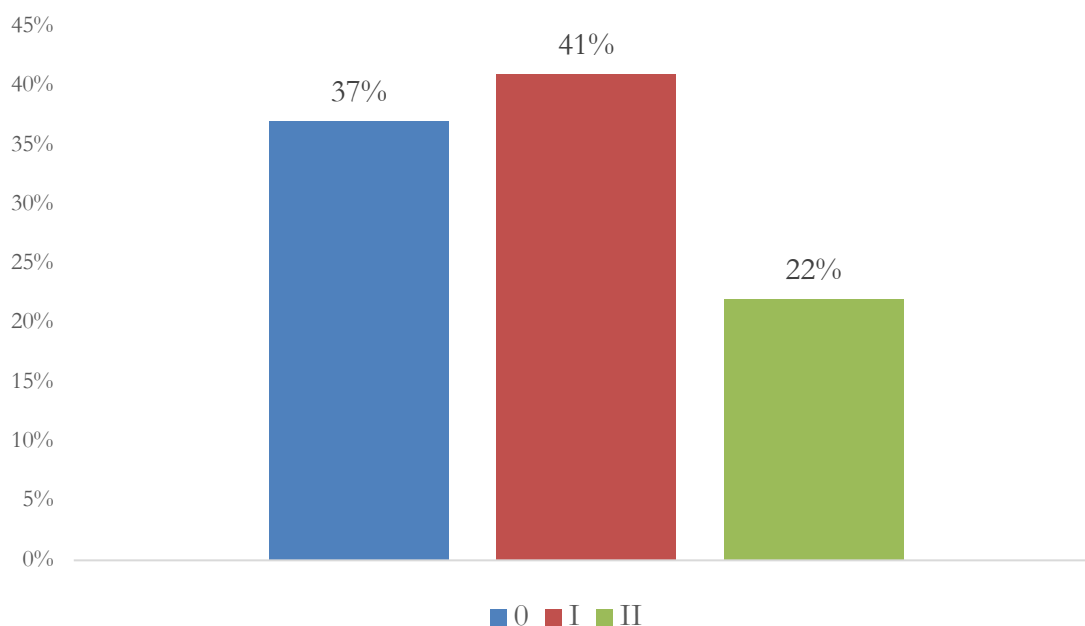
Table 7 shows the relation between astigmatism and the refractive power of the patients. The sum of the patient collective for astigmatism does not add up to 24 patients but only 19 as noted in Table 7. The reason for this is that not each medical report included astigmatism and refractive power together. This table only refers to patients with information for both refractive power and astigmatism. Out of 19 patients who had an astigmatism, 15 (79%) also had hyperopia. Or counter-wise, out of 21 patients with hyperopia, 15 (71%) had an astigmatism. The one patient with myopia had an astigmatism and the rest of the patients with normal eyesight had an astigmatism to 23%.

Table 7 Relation between astigmatism and refractive power

Refractive power	Patients with Astigmatism			Total
	yes	no	N/A	
N/A	0 (0%;0%)	0 (0%;0%)	11 (42.3%;100%)	11 (23.9%)
Myopia	1 (5.3%;100%)	0 (0%;0%)	0 (0%;0%)	1 (2.2%)
Hyperopia	15 (78.9%;71.4%)	0 (0%;0%)	6 (23.1%;28.6%)	21 (45.7%)
Emmetropia	3 (15.8%;23.1%)	1 (100%;7.7%)	9 (34.6%;69.2%)	13 (28.3%)
Total	19 (41.3%)	1 (2.2%)	26 (56.5%)	46 (100%)

3.2.3 Stages of Alport syndrome, severity of the variants, and the kidney progress

Figure 8 demonstrates that the majority of patients was in AS I, including 19 patients (41%), followed by stage 0 with 17 patients (37%). Ten patients (22%) were in stage II.

**Figure 8** Percentage of patients with Alport stages 0, I, and II, n = 46

The severity of variants can be divided into mild, moderate, and severe. Seven patients (15%) had a variant categorized as mild, 24 (52%), over half of the patients had a variant categorized as moderate, and 15 (33%) a variant categorized as severe, as shown in Table 8.

Table 8 Inheritance and severity of the variant

Inheritance	Severity of the variant			Total
	mild	moderate	severe	
X-linked	7 (100%;18.4%)	19 (79.2%;50%)	12 (80%;31.6%)	38 (82.6%)
autosomal	0 (0%;0%)	5 (20.8%;62.5%)	3 (20%;37.5%)	8 (17.4%)
Total	7 (15.2%)	24 (52.2%)	15 (32.6%)	46 (100%)

Out of 38 patients who expressed a X-chromosomal linked inheritance, seven patients (18%) had a mild variant, 19 patients (50%) a moderate, and twelve patients (32%) a severe variant. Out of the eight patients with an autosomal inheritance, none showed a mild variant, leaving five (63%) with a moderate variant, and three (38%) with a severe variant.

A progress in the kidney disease was found in 16 (35%) out of the 46 Alport patients. 30 patients (65%) did not have a progress.

An eye progress was only found in one patient which will be discussed in 3.2.4.

3.2.4 Correlation of ocular and renal parameters

The correlation of ocular and renal parameters was examined.

Refractive power and the severity of the variant were compared with each other, as shown in Table 9. The patient with myopia had a variant categorized as severe. Out of 21 patients with hyperopia, three patients (14%) had a variant categorized as mild, nine patients (43%) had a variant categorized as moderate, and also nine patients (43%) as severe. Out of 13 patients with emmetropia, three patients (23%) had a variant categorized as mild, six (46%) had a variant categorized as moderate, and four (31%) as severe.

Table 9 Refractive power and severity of the variant

Refractive power	Severity of the variant			Total
	mild	moderate	severe	
N/A	1 (14.3%;9.1%)	9 (37.5%;81.8%)	1 (6.7%;9.1%)	11 (23.9%)
Myopia	0 (0%;0%)	0 (0%;0%)	1 (6.7%;100%)	1 (2.2%)
Hyperopia	3 (42.9%;14.3%)	9 (37.5%;42.9%)	9 (60%;42.9%)	21 (45.7%)
Emmetropia	3 (42.9%;23.1%)	6 (25%;46.2%)	4 (26.7%;30.8%)	13 (28.3%)
Total	7 (15.2%)	24 (52.2%)	15 (32.6%)	46 (100%)

The refractive power can also be related to different Alport stages. The myopic patient was in Alport stage II. Out of a total of 21 hyperopic patients, seven patients (33%) had Alport stage 0, eight patients (38%) were in stage I, leaving six patients (29%) in stage II. The majority of emmetropic patients, (seven patients (54%)), were in stage 0, followed by five patients (39%) in stage I, and one patient (8%) in stage II, as shown in Figure 9.

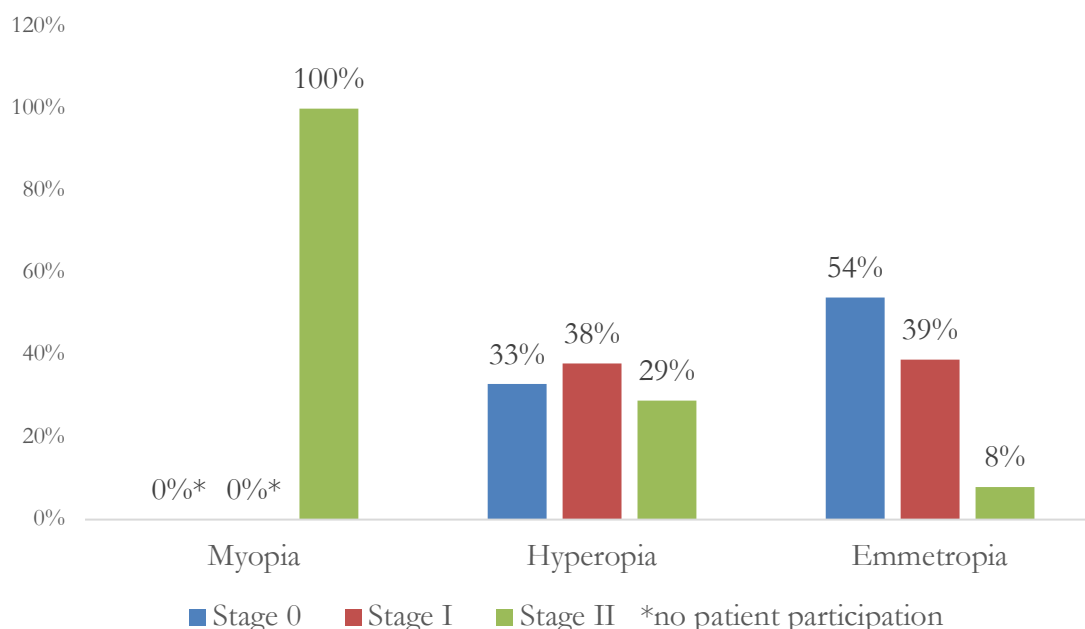


Figure 9 Relation between refractive power and Alport stages, n = 46

In total, 16 (35%) out of the 46 patients had a kidney progress whereas 30 patients (65%) did not.

The myopic patient did not show a kidney progress. Six patients (29%) of the 21 patients with hyperopia had a progress. Six patients (46%) of the 13 emmetropic patients also had a kidney progress.

The parameters severity of the variant, stages of AS and progress in the kidney can be compared with the astigmatism. Out of 24 patients with an astigmatism, three patients (13%) had a variant categorized as mild, nine (38%) had a variant categorized as moderate, and twelve (50%) had variant categorized as severe, shown in Figure 10.

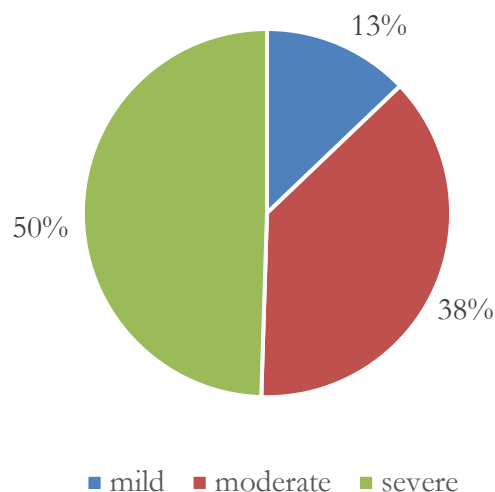


Figure 10 Severity of the variant in patients with astigmatism, n = 46

Regarding the Alport stages, six (25%) of the 24 patients with an astigmatism were in stage 0, followed by ten patients (42%) in stage I, and eight patients (33%) in stage II. Most patients with an astigmatism had a variant categorized as severe and an Alport stage I. Ten (42%) of 24 patients with an astigmatism showed a progress in the kidney while 14 (58%) of the patients with an astigmatism did not show a progress.

Eight of the 46 patients (17%) patients had family members who also had ocular irregularities. Yet, there was no correspondence between patients with Alport specific ocular changes and family members with ocular changes.

An ocular progress was only found for one patient. This patient was male, 15 years old at the first inspection and had a X-chromosomal linked inheritance. He had a variant categorized as mild with an AS stage 0 and a kidney progress after three years, together with an ocular progress. His refractive power was normal, an astigmatism was not noted. After three years during the third examination, an inflammation along the edges of the eyelids was found along with corneal vascularization.

4 Discussion

This dissertation examines ocular changes of children that participated in the EPA trial. It is evaluated what kind of ocular changes these children showed and if these changes are characteristic for AS. The relation between the ocular changes, age, and stages of the kidney disease is examined in this chapter. The results of the ocular medical reports collected in the EPA trial are discussed in context with studies which also investigated ocular changes in Alport patients. The following discussion focuses on astigmatism, refractive power, and the Alport specific ocular changes such as macular thinning, macular pigment, vitreous body degeneration, lenticonus, and retinopathy. Examination methods, patient ages, and kidney stages are further aspects of this discussion.

4.1 Summary of main results

98% of the patients in this trial were male and 2% were female.

On average, the patients were eight years old (± 4). Most patients had their first ocular examination at the age of nine (± 4).

The majority of the patient collective showed an astigmatism (52%), of which most were in Alport stage I and showed a variant categorized as severe.

45% of the patients were hyperopic, in stage I (41%), and showed a variant categorized as moderate (52%).

An Alport specific eye phenotype was seen in 5 patients (10%). This included macula thinning, macula pigment, and vitreous body destruction. These five patients showed variants categorized as moderate to severe and were in Alport stage I. They had an astigmatism and a tendency to hyperopia or emmetropia. On average these patients were seven to ten years old.

4.2 Discussion of results

4.2.1 Astigmatism

52% ($n = 24$) of the EPA patient collective of Alport patients exhibited astigmatism. In relation to the kidney parameters, the majority, 41% ($n = 10$), of these patients was in Alport stage I. 50% ($n = 12$) of the patients with astigmatism had a variant categorized as severe, followed by 38% ($n = 9$) variant categorized as moderate. Based on these data, a trend can be observed that Alport patients tend to develop astigmatism. Each patient in the EPA trial with an Alport specific ocular abnormality, except the one with macular pigment, had astigmatism. These astigmatic patients tended to have a variant categorized as moderate to severe, rather than mild. Literature regarding astigmatism and the correlation with the genotype does not exist. The refractive power of 19 astigmatic patients could be examined.

79% (n = 15) of the astigmatic patients in this trial were hyperopic. The single myopic patient also had astigmatism. The high incidence of hyperopia and astigmatism in the EPA trial does not coincide with other studies. Studies suggested that astigmatism can be associated with myopia (Fulton et al. 1982; Gwiazda et al. 2000; Read et al. 2007; Suranyi et al. 2019).

Suranyi et al. conducted a study with seven patients from 2014 to 2015 in which a 29 year old patient was diagnosed with astigmatism and myopia (Suranyi et al. 2019).

Fulton et al. examined 298 myopic children which were up to ten years old and discovered that children with astigmatism were associated with higher degrees of myopia than children who did not have astigmatism (Fulton et al. 1982).

Gwiazda et al. examined 245 children with a mean age of 13 years and described that astigmatism after age seven is associated with myopia and less hyperopia (Gwiazda et al. 2000).

The different outcomes between the studies mentioned above and the EPA trial could be explained with the participation of just one myopic patient in the EPA trial. Although a tendency can be observed that Alport patients have astigmatism, this statement has to be cautioned by the fact that data could only be retrieved from 54% of the patients.

The relation between astigmatism and kidney parameters could not be compared because of a lack of literature.

However, the prevalence of astigmatism in patients with AS can be compared to the prevalence in the population without AS. According to Read et al., astigmatism occurs in 13% of all refractive errors in the healthy population (Read et al. 2007). In the EPA trial 52% of Alport patients had astigmatism. Studies describe similar percentages in patient populations without AS (Fledelius and Stubgaard 1986; Satterfield 1989).

A study by Satterfield performed 1989 in a military population of 1112 patients aged 20 to 30 years, depicted astigmatism in 63% (n = 701) of the collective (Satterfield 1989). Fledelius examined 454 patients aged 5 to 80 years old and found astigmatism in 46% (n = 209) of the population (Fledelius and Stubgaard 1986).

On average, EPA trial patients with astigmatism were nine years old. This corresponds to the findings of Hirsch in which astigmatism predominates until the age of nine (Hirsch 1963; Gwiazda et al. 1984). At the time of the ocular examination in the EPA trial, the youngest patient was one year old and the oldest was 20 years old. Infants and patients show a high prevalence of a high degree astigmatism in early stages of their life (Gwiazda et al. 1984; Read et al. 2007). Gwiazda et al. examined 1000 children who were up to six years old. In the study a high prevalence of astigmatism was found, especially in the first two years (Gwiazda et al. 1984). As infants grow, the cornea flattens and the degree of astigmatism reduces (Read et al. 2007). By reaching school age, astigmatism usually eliminates or reduces further (Gwiazda et al. 1984). Astigmatism in young adults under the age of 40 is mostly low and occurs commonly (Read et al. 2007).

Two more recent studies of younger patients without AS demonstrate lower percentages of astigmatism which do not coincide with the percentages of the EPA trial. In 2011, Fozailoff et al. conducted a study with 2994 African American children and 3030 Hispanic children who were six to 72 months old. The prevalence of astigmatism was 13% (n = 389) in the African American children and 17% (n = 515) in the Hispanic children (Fozailoff et al. 2011). A study by Ying examined 4040 three to five year old children from the United States and found a prevalence of 4 to 11% (n = 162 to 444) (Ying et al. 2014).

In a study conducted by Mutti in 2004, 298 children who were three to 36 months old were examined using video-based keratophacometry and ultrasonography over the closed eye in addition to cycloplegic retinoscopy. The previously mentioned studies concentrated on cycloplegic retinoscopy. In Mutti's study astigmatism was found in 42% (n = 125) of infants aged three months old. A significantly lower percentage of 4% (n = 12) was seen in children who were 36 months old (Mutti et al. 2004). This decrease of astigmatism as children become older corresponds to the observations in the studies mentioned above of Gwiazda et al. and Read et al. (Gwiazda et al. 1984; Read et al. 2007)

The Gutenberg Health Study published in 2016 examined 13959 patients in Germany to evaluate the refractive power and astigmatism. Patients were between 35 and 75 years old. The prevalence of astigmatism was 32.3% (n = 4509) (Wolfram et al. 2014).

Older studies, for example these of Fledelius and Satterfield, argue that astigmatism with 46% and 63% is high in the healthy population. More recent studies by Mutti et al., Fozailoff et al., Ying et al., and Wallace et al. show that astigmatism is below 15% in the healthy population. A study comparison is shown below in Table 10.

Table 10 Astigmatism in EPA Alport patients compared to astigmatism in healthy patients of cited studies

Studies	EPA (2019)	Gutenbg. (2016)	Ying (2014)	Fozailoff (2011)	Mutti (2004)	Satterfield (1989)	Fledelius (1986)
n (total) =	46	13959	4040	2994-3030	298	1112	454
Astigmatism patients (%)	52	32	4-11	13-17	4	63	46
Age	1-20 years	35-75 years	3-5 years	6-72 months	3-36 months	20-30 years	5-80 years

Compared to the low percentages of astigmatism from these recent studies, the high percentages of astigmatism in the EPA trial data could indicate that patients with AS have a higher tendency to develop astigmatism than patients without AS.

An explanation for the various outcomes in the studies could be the different settings in each study such as the age of the patients, the examinations, and the classification of astigmatism. In the EPA trial it was not differentiated in diopters between a high and a low astigmatism.

Certain studies defined astigmatism after a certain dioptic value. This detailed information was not always noted in the medical reports of the EPA patients. The EPA medical reports often only noted if astigmatism was generally existent or not. In addition, the cited studies are larger than the EPA trial and show a greater statistic power.

4.2.2 Myopia

In the EPA trial 2% ($n = 1$) of the children had myopia. This patient was 14 years old at the time of the examination. He was in Alport stage II and had a variant categorized as severe. Although for a statistic evaluation one patient is not sufficient, the 2% of myopia found in the EPA trial matches with the average percentage of myopia found in studies of the healthy population.

Ying et al. examined 4040 children from the United States who were three to five years old. The children were examined with cover testing and cycloplegic retinoscopy. 0.2% ($n = 8$) to 2% ($n = 81$) of these children had myopia (Ying et al. 2014).

A study by Ojaimi et al. showed similar results. The study examined myopia among 1765 Australian children who were on average seven years old. The prevalence of myopia was 1.43% ($n = 25$) (Ojaimi et al. 2005).

In the Baltimore study 2546 American children who were six to 71 months old were examined. Myopia was found in 0.7% ($n = 18$) of white children and in 6% ($n = 153$) of African-American children (Giordano et al. 2009). According to the Gutenberg Health Study of 2014, the prevalence of myopia was 35.1% ($n = 4900$) in 13959 healthy 35 to 75 year old patients in Germany (Wolfram et al. 2014).

The statistic power of the studies above is greater than in the EPA trial due to a larger patient collective. One myopic patient is not enough in order to compare myopia in Alport patients with myopia in the healthy population. Further studies with a higher number of myopic patients with AS would need to be done for a more reliable comparison.

4.2.3 Hyperopia

46% ($n = 21$) of the EPA patients were hyperopic. Most of these patients were five years old at the time of the examination. The youngest hyperopic patient was three years old. 43% ($n = 9$) of these hyperopic patients had a variant categorized as severe. Also 43% ($n=9$) of the hyperopic patients had a variant categorized as moderate. Only 14% ($n = 3$) of patients with hyperopia had a variant categorized as mild. These data indicate that AS patients with a variant categorized as severe or moderate are more likely to become hyperopic.

Studies which examined hyperopia in the population without AS observed similar percentages of hyperopia.

Ying et al. examined 4040 children who were three to five years old and observed hyperopia in 40% ($n = 1616$) (Ying et al. 2014).

The multi-ethnic pediatric eye disease study in 2010 examined 2994 African American and 3030 Hispanic children who were six to 72 months old. Hyperopia was found in 27% (n = 808) of the African American children and in 21% (n = 636) of the Hispanic children, adding up to a total of 48% patients with hyperopia (Multi-Ethnic Pediatric Eye Disease Study Group 2010).

Mohindra and Held examined 400 children who were up to five years old and observed a prevalence of hyperopia of 35% (n = 140) (Mohindra and Held 1981).

The Gutenberg Health Study with 13959 patients found a prevalence of 31.8% (n = 4439) in healthy hyperopic patients who were 35 to 75 years old (Wolfram et al. 2014).

In contrast to these four studies that support the results of the EPA trial, the Baltimore study had a different outcome (Giordano et al. 2009). Giordano et al. examined 2546 American children who were six to 71 months old and found hyperopia in 9% (n = 229) of white children and in 4% (n = 102) of African-American children.

The studies of Ying et al., Multi-Ethnic Pediatric Eye Disease Study Group, Mohindra and Held, and the Gutenberg Health Study observed percentages between 30% and 48% of hyperopia in healthy patients. Alport patients in the EPA trial showed a similar prevalence of hyperopia with 46%. This can lead to the assumption that patients with AS do not have a higher tendency to develop hyperopia than patients without AS.

4.2.4 Macular thinning

2% (n = 1) of the EPA patients had macular thinning. This patient was male and had an autosomal mode of inheritance. He was 20 years old and in Alport stage II. He had a variant categorized as moderate and had hyperopia as well as astigmatism.

The following studies also observed temporal macular or temporal retinal thinning in Alport patients.

Bemme et al. found four out of five patients with severe temporal macular thinning in their patient collective of XLAS Alport patients. In contrast to the low percentage of macular thinning in the EPA trial, Bemme et al. stated that temporal macular thinning is one of the most common ocular symptoms of AS (Bemme 2015).

A study conducted by Ahmed et al. with 32 XLAS patients also showed a high occurrence (70%) (n = 22) of temporal macular thinning (Ahmed et al. 2013). Examinations done in both studies of Bemme et al. and Ahmed et al. included retinal imaging using an OCT and fundus photography (Ahmed et al. 2013; Bemme 2015). These examination methods were also documented in the medical report of the EPA patient with macular thinning.

Ahmed et al. observed a presence of the X-linked COL4A5 gene in every patient of his study. In his study temporal macular thinning is associated with an X-chromosomal form of inheritance and COL4A5 variants (Ahmed et al. 2013). Kashtan also examined a link between

XLAS and maculopathy (Kashtan 2003). This does not coincide with the patient of the EPA trial, who had an autosomal form of inheritance.

Jais et al. examined 162 male patients with a COL4A5 variant for ocular changes and discovered maculopathy in 14% (n = 23). In comparison to the observation of Ahmed and Kashtan, Jais et al. could not find a significant correlation with a COL4A5 variant (Jais et al. 2000).

Fawzi et al. found temporal retinal thinning in one of nine Alport patients using a Fourier domain OCT (Fawzi et al. 2009). This patient was 19 years old.

Chen et al. examined 47 Alport patients. Of 19 male patients, 89% (n = 17) had temporal retinal thinning. Of 28 female patients, 75% (n = 21) had temporal retinal thinning. Chen et al. observed that temporal retinal thinning is more pronounced and severe in male XLAS patients than in female XLAS patients (Chen et al. 2018). In addition to OCT, examinations performed were retinoscopy, ophthalmoscopy, slit-lamp biomicroscopy, and retinal photography. Chen et al. state that temporal retinal thinning is relatively specific for XLAS in men with renal failure and is linked to early-onset renal failure (Chen et al. 2018). In the EPA trial, this statement could not be confirmed since the EPA patient with macular thinning had not yet reached ESKD.

A recent study of K. Hess demonstrated a presence of foveal changes in Alport patients using OCT (Hess et al. 2020). Observed ocular changes were foveal hypoplasia and a staircase-like thinning of the inner retinal layers, previously called “staircase-foveopathy”. Hess et al. suggest that type IV collagen, which is present in Bruch’s membrane and inner limiting membrane plays an important role in foveal development and maintenance of inner retinal layers. The presence of foveal changes shows the heterogeneity of the disease and that not all characteristics of ocular involvement in AS have been described in literature.

A study comparison can be seen in Figure 11. The table shows that temporal macular and retinal thinning is common in patients with AS. In comparison to the EPA trial, high percentages of temporal macular and retinal thinning were found in the cited studies. However, only one EPA patient was examined with OCT. The cited studies applied OCT to all patients. If more patients of the EPA trial were examined with OCT, temporal macular and retinal thinning could have possibly been found in more patients. This demonstrates the importance of elaborated examination methods such as OCT.

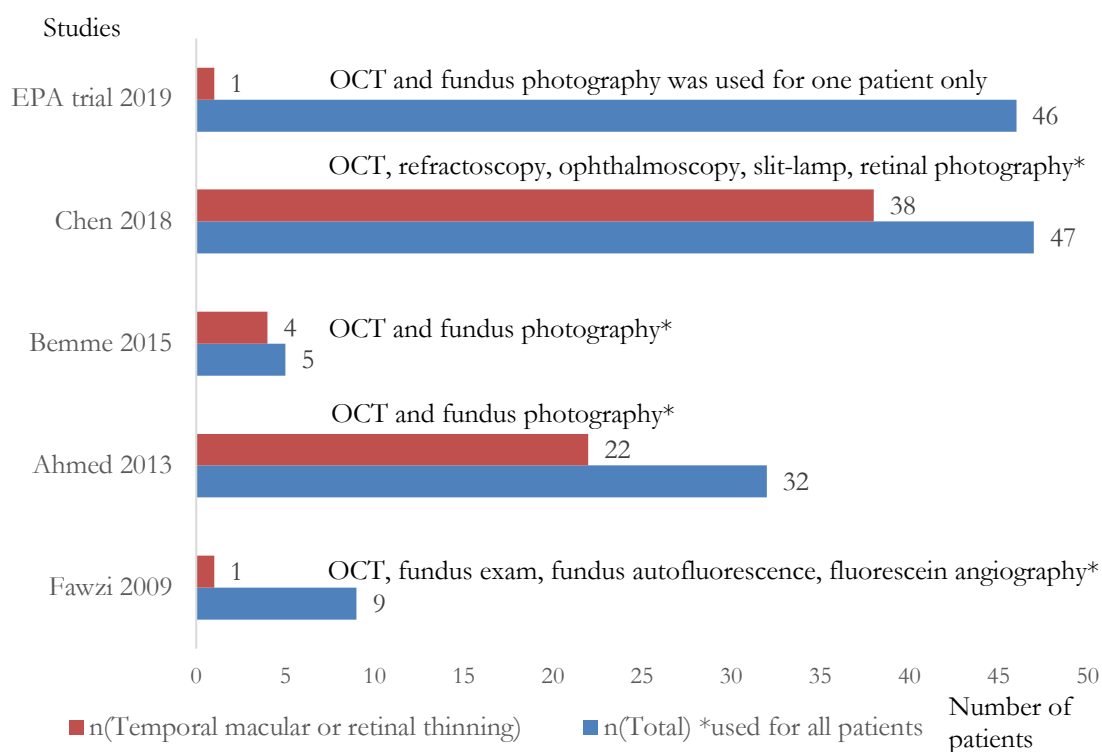


Figure 11 Patients with temporal macular or retinal thinning in cited studies with related examination methods

There are case reports of OCT findings of Alport patients with temporal and perimacular thinning.

Cho et al. reported one patient with AS and temporal macular thinning who was 24 years old (Cho et al. 2017).

Gupta et al. examined two Alport patients who were 19 and 24 years old with temporal macular thinning (Gupta et al. 2019). The 19 year old patient in the case report of Gupta et al. was myopic (Gupta et al. 2019). In contrast, the EPA patient was hyperopic.

The patients of selected studies had a similar age at the time of the investigations. EPA patient 20 years old, Fawzi patient 19 years old, Cho patient 24 years old and Gupta patients 19 and 24 years old. This suggests that temporal retinal thinning is more likely to be found in adolescent Alport patients than in very young patients. However, in order to notice a significant correlation between the age or the severity of the variant and macular thinning a larger number of Alport patients with temporal retinal thinning needs to be included in further studies.

4.2.5 Macular pigment

2% (n = 1) of the EPA trial had macular pigment. This patient was male and had an X-chromosomal form of inheritance. He had a variant categorized as moderate, was in Alport

stage I, and showed a kidney progress. His eyes were emmetropic without astigmatism. A fundus examination was documented in the medical report. At the time of the diagnosis, the EPA patient was ten years old. This age is different to the age of the patients in the following mentioned studies, who were on average six, 19, 22.5, and 24 years old.

Already in 1981, it could be proven that Alport patients can have macular lesions and pigment (Gubler et al. 1981). Gubler et al. conducted a study in which 18 of 26 Alport children showed macular changes (Gubler et al. 1981). At the time of diagnosis, the patients were on average six years old. In five children macular changes manifested as an enlargement and abnormal pigmentation of the macula. 13 children had yellow or white granular lesions around the fovea. Most of these patients had hematuria, frequent proteinuria, and developed terminal renal failure (Gubler et al. 1981).

Similar findings of macular pigment could be found in the studies of Govan, Thompson, Perrin et al., Jais et al., and Fawzi et al. (Perrin et al. 1980; Govan 1983; Thompson et al. 1987; Jais et al. 2000; Fawzi et al. 2009).

Govan observed pale yellow flecks mainly in the temporal region of the macula in 14 of 16 patients (Govan 1983). These patients were on average 24 years old and had chronic renal failure. They were on dialysis or had received a renal transplant. Ocular examinations included subjective and objective refraction, ophthalmoscopy, fundus photography, an electroretinogram, and an electrooculo-gram (Govan 1983). Five of these 14 patients were myopic and eight patients had astigmatism. In contrast, the EPA patient was emmetropic and did not show astigmatism.

Thompson et al. conducted a study with 42 Alport patients. These patients had hematuria with or without proteinuria and renal failure. They were on average 23 years old. He observed perimacular flecks in three patients (Thompson et al. 1987). Ocular examinations included ophthalmoscopy, slit lamp, stereo lamp, fundoscopy, and visual acuity.

The study by Perrin et al. with 79 patients conducted from 1962 to 1977 discovered symmetric, bilateral perimacular changes in 29 patients (Perrin et al. 1980). These changes were characterized through bright white and yellow granulations around the fovea. It was notable that patients with macular flecks experienced an earlier onset of renal failure than patients without macular flecks (Perrin et al. 1980). Patients in the studies described above often had renal failure and were on dialysis or had a kidney transplant. In comparison, the patient of the EPA trial did not have renal failure.

A more recent study of Jais et al. observed macular flecks in 15% ($n = 52$) of the patient collective of 349 patients (Jais et al. 2003). The patients were female and between one and 57 years old. Most of these patients developed proteinuria. Patients of this study were on average younger than two years old when they were diagnosed with hematuria.

A study of Fawzi et al. with nine patients discovered macular flecks in one 19 years old Alport patient. The examination methods in this study were fundus exam, fluorescein angiography,

fundus autofluorescence, and high-resolution OCT (Fawzi et al. 2009). This patient had early-onset disease and was on dialysis. He had experienced a post-transplant anti-GBM rejection.

Table 11 shows the percentages of macular pigment and the kidney information noted in these studies.

Table 11 Macular pigment, kidney status, and examination methods in cited studies

Studies	EPA trial (2019)	Fawzi (2009)	Jais (2003)	Thompson (1987)	Govan (1983)	Gubler (1981)
n (total) =	46	9	349	42	16	26
Macular pigment patients (%)	2	11	15	7	88	69
Age in years	10	19	1-57	23	24	6
Kidney status	Alport stage I	ESKD	Protein-uria	ESKD	ESKD	ESKD
Examination methods	Funduscopy	Funduscopy, fluorescein angiography, fundus autofluorescence, and high-resolution OCT	N/A	Ophthalmoscopy, slit and stereo lamp, funduscopy	Ophthalmoscopy, fundus photography, electroretinogram, and electrooculogram	N/A

It can be said that macular pigment can be found in children as well as in adults with AS. Including children, many of these patients had ESKD. Although the total number of children of these studies is lower compared to the number of adults, it can be seen that there is no characteristic difference between children and adults.

The findings of the EPA trial indicate that macular thinning and macular pigment could be linked to AS. This has also been documented in the studies mentioned above. However, in contrast to the EPA trial which used regular ocular examinations, the other studies included additional examinations such as fluorescein angiography, fundus autofluorescence, and high-resolution OCT. This may have impacted the result comparison between the EPA trial and the other studies mentioned above.

4.2.6 Further macular findings

Macula changes diagnosed in the EPA trial patients were macular thinning and macular pigment. Further macular changes in Alport patients were found in the studies of Fawzi et

al. and Savige et al. These studies described a bull's eye maculopathy and a vitelliform maculopathy (Fawzi et al. 2009; Savige et al. 2017). The study of Fawzi et al. with nine patients identified one 19 year old patient with a bull's eye maculopathy. This was characterized as macular staining in a bull's eye pattern in the right eye. Fluorescein angiography, OCT, a fundus exam as well as fundus autofluorescence were used for the examinations (Fawzi et al. 2009). Another patient, 56 years old, of this study showed macular vitelliform detachment lesions in both eyes and peripheral retinal flecks. Examinations performed were fundus autofluorescence imaging, high-resolution OCT, and fluorescein angiography (Fawzi et al. 2009). Both patients of the study of Fawzi et al. were male and in late stages of the disease with a renal transplantation. In comparison to the EPA trial, neither the EPA patient with macular pigment nor the EPA patient with macular thinning had renal failure.

The study of Savige et al. conducted with 69 patients also found a bull's eye maculopathy in one Alport patient. This patient was female and had a normal renal function. Savige et al. stated that this maculopathy may result from a damaged Bruch's membrane which can affect the vision (Savige et al. 2017).

The above studies show that the macula can often be affected in Alport patients. It does not necessarily have to be macular pigment or macular thinning but can also be related to other maculopathies such as a vitelliform or bull's eye maculopathy.

Although these studies examined mainly adult patients these types of ocular changes should not be ignored when diagnosing children for AS. This comment is made since macular thinning and macular pigment could also be found in children and adults, see chapter 4.2.4 and 4.2.5.

4.2.7 Vitreous body degeneration

Vitreous body degeneration or opacity was found in 7% (n = 3) of the EPA patients. Each of these patients was male, in Alport stage I, and had astigmatism. Anterior segment and funduscopy were used as eye examination. A vitreous body degeneration has to be severe in order to be observed in a regular ocular exam and is pathologic in young patients. Therefore, it can be discussed that a vitreous body degeneration in Alport patients is so pronounced that it is often noticeable.

In 2003 Shaikh et al. reported the first case of vitreous body degeneration associated with AS (Shaikh et al. 2003). A fundoscopic examination showed posterior vitreoretinal degeneration and retinal detachment in a male patient with renal failure who was 49 years old (Shaikh et al. 2003). The EPA patients with vitreous body degeneration were much younger (7, 8, and 10 years old) than the patient of Shaikh's et al. case report. In comparison to the patient of the study of Shaikh et al., the EPA children had not reached ESKD. This demonstrates that vitreous body degeneration can occur at a young age and before renal failure in Alport patients. Therefore, in order to gain more information on the ocular changes

in AS, it can be discussed that it is beneficial to examine children with AS for vitreous body degeneration.

The three EPA children had a variant categorized as either moderate or severe. This could indicate that AS patients with a variant categorized as severe or moderate are more likely to develop a vitreous body degeneration or opacity than patients with a mild variant.

While the patient of the case report of Shaikh et al. was myopic, the EPA children were hyperopic or emmetropic. Due to the fact that each patient had a different refractive power, no relation could be seen between vitreous body degeneration and refractive power. Another notable aspect is that the patient of Shaikh et al. demonstrated retinal detachment in addition to the vitreous body destruction. In contrast, the ocular reports of the EPA children documented an attached retina. This difference in the ocular findings shows that a vitreous body degeneration does not have to be accompanied by retinal detachment.

Shaikh et al. suggest ophthalmologists to be aware of the possibility of vitreous body degeneration and retinal detachment when examining the anterior segment and fundus of Alport patients (Shaikh et al. 2003). The findings of the EPA trial support this statement.

4.2.8 Additional ocular changes found in other studies

4.2.8.1 Lenticonus anterior

Although lenticonus anterior is known to be a pathognomonic AS symptom, it was not detected in EPA patients (Kashtan 2003).

Lenticonus anterior was described in many studies with Alport patients (Kashtan 2003; Shaw et al. 2007; Zhang et al. 2008; Savige et al. 2010; Tan et al. 2010). Already in 1997 Colville and Savige stated that lenticonus occurs in 25% of affected male patients (Colville and Savige 1997). In 1980 Perrin discovered lenticonus anterior with fundoscopic examination in 29 of 79 patients (Perrin et al. 1980).

Savige et al. conducted a study including four male and four female patients with XLAS and three male patients with ARAS (Savige et al. 2010). On average these eleven patients were 35 years old and had an early onset of renal failure. Lenticonus was detected in two of the male patients with XLAS and in the three male patients with ARAS. To diagnose the lenticonus the eyes were examined for the oil-droplet sign with a retinoscope.

A study of Hentati et al. examined 32 patients for ocular changes. 28% (n = 9) of the patients showed lenticonus anterior, similar to the 25% of the patients in the study of Colville and Savige (Hentati et al. 2008).

Shaw's et al. study included 26 patients (Shaw et al. 2007). Lenticonus was found in 70% (n = 18) of male patients with XLAS and in 100% of patients with ARAS. The patients were examined for the oil-droplet sign with a hand-held refractoscope. Most patients of the study had an early onset of renal failure (Shaw et al. 2007).

Studies of Jais et al., Gross et al., and Savige et al. examined a relation between lenticonus, COL4A5 variants, and early-onset renal failure.

Jais et al. observed a genotype-phenotype correlation of lenticonus in 195 families which had the COL4A5 gene. (Jais et al. 2000). All patients had hematuria and 95% showed proteinuria (Jais et al. 2000). Out of 162 patients who were examined for ocular changes, 13% (n = 35) had lenticonus. Lenticonus was more likely to occur in patients who had a large COL4A5 deletion than in patients with splice site or missense variants. Patients with large COL4A5 deletions tended to develop early-onset renal failure (27 families) (Jais et al. 2000). 78% (n = 282) of the 360 patients with follow-up investigations progressed to ESKD.

In a study with 276 patients, Gross et al. described that COL4A5 variants in male XLAS patients have a tendency to lead to early-onset renal failure and lenticonus (Gross et al. 2002). Ocular data was received for 49 patients. 57% (n = 28) of these 49 patients had lenticonus. In five patients who had lenticonus large rearrangements were verified. Gross et al. also discovered that large protein structure changes are very likely to lead to an early onset of ESKD (Gross et al. 2002). Similar findings that support this assumption were found by Savige et al. who examined a link between nonsense variants in the COL4A5 gene, early onset ESKD, and lenticonus (Savige et al. 2016).

Figure 12 shows an overview of the number of patients affected with lenticonus in the different studies. It presents that lenticonus is often found in Alport patients. The examinations performed to diagnose lenticonus were refractoscopy to look for the oil-droplet sign and funduscopy.

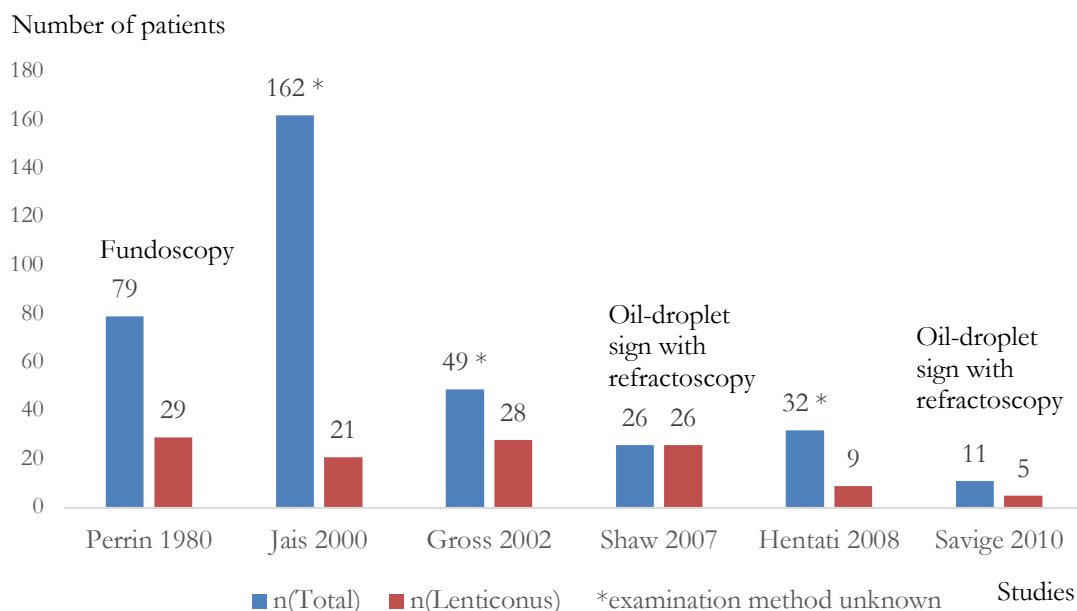


Figure 12 Number of patients with lenticonus in cited studies with related examination methods

4.2.8.2 Retinopathy

Retinopathy is another characteristic ocular symptom of AS. It has been linked to lenticonus and early-onset renal failure (Savige et al. 2015).

Several studies detected retinopathies in Alport patients. Bemme et al. observed peripheral retinopathy in 20% (n = 1) of his study with 5 patients (Bemme 2015). This patient was male with XLAS (Bemme 2015). OCT, slit-lamp, ophthalmoscopy, fundus autofluorescence, fundus photography, as well as multicolor imaging were used in this study as examination methods.

In the study of Zhang et al. 15 male patients who were on average eleven years old were examined. 33% (n = 5) of these children had central or peripheral flecks which often preceded the early onset of renal failure (Zhang et al. 2008). Zhang et al. used a retinoscope to look for the oil-droplet sign, pupil dilation and fundoscopy, and slit-lamp to examine the eyes. Zhang et al. suggested to examine male Alport patients more than ten years old for retinopathies using retinal examinations and photography (Zhang et al. 2008). They stated that an eye examination can be helpful to diagnose AS even before the onset of renal failure.

A similar percentage of retinopathy was found in the study of Hentati et al. conducted with 32 patients. They observed retinal flecks in 37% (n = 12) of the patient collective (Hentati et al. 2008).

Shaw et al. examined 26 Alport patients. Most of the patients had renal failure. 62% (n = 16) of these patients had central retinopathy and 74% (n = 19) had peripheral retinopathy (Shaw et al. 2007). The patients were partially affected with both central and peripheral retinopathy. Retinal photography and a dilation of the pupils were used to diagnose retinopathy. The study stated that peripheral retinopathy was more likely to occur if central retinopathy, lenticonus, and renal failure were already present (Shaw et al. 2007).

Fawzi et al. discovered central retinal flecks in one patient, peripheral retinal flecks in another patient and both types of flecks in two different patients of their study with nine Alport patients (Fawzi et al. 2009). The examinations performed were fundus autofluorescence and high-resolution OCT. Each patient had reached ESKD. They were on dialysis or had received a renal transplant.

Shaw et al., Savige et al., and Fawzi et al. stated that retinopathy is linked to an early onset of renal failure.

Another type of retinopathy related to AS is the dot and fleck retinopathy (Tan et al. 2010).

Using fundus photography and autofluorescence imaging, dot and fleck retinopathy was found in a patient of the study of Cho et al. (Cho et al. 2017). This patient was 24 years old with a COL4A3 variant and had a renal transplant (Cho et al. 2017).

A study of Shaw discovered dot and fleck retinopathy in 8 of 10 examined patients. These patients were male, up to 54 years old. Most of the patients were on dialysis or had received a renal transplant (Shaw et al. 2007).

Tan et al. discussed that dot and fleck retinopathy confirms the diagnosis of AS and predicts a tendency to a higher risk of developing early-onset renal failure (Tan et al. 2010).

These studies demonstrate that retinopathy is a common symptom of AS and can be found in children as well as in adults. Retinopathy was described that it is often associated with early-onset renal failure. Studies of Savige et al. and Shaw et al. showed that children who exhibit lenticonus are likely to be affected by retinopathy. Therefore, when children or adults are diagnosed with lenticonus, the possibility of retinopathy should be considered. Knowing that retinopathy is a characteristic symptom of AS can be useful to confirm the diagnosis of AS in adults and in children. An overview of the study findings including the related examination methods is presented in Figure 13.

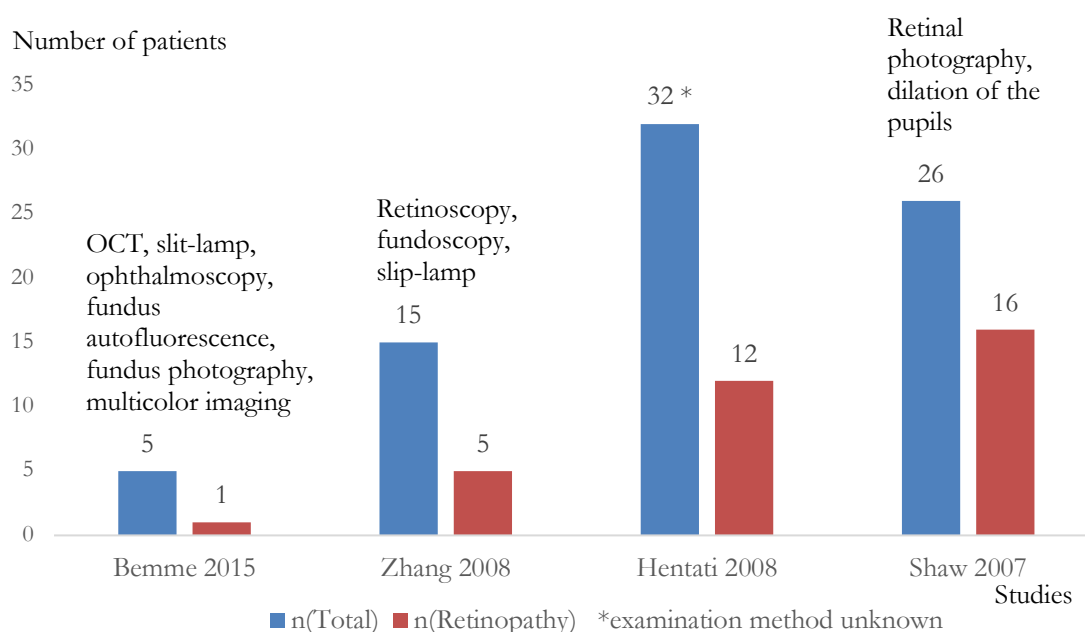


Figure 13 Patients with retinopathy in cited studies with related examination methods

4.2.9 Variant

The results of the EPA trial could indicate that there is a relation between severe variants and ocular changes in AS. The findings of the EPA trial showed that EPA patients who had variants categorized as moderate or severe were more likely to have Alport specific ocular changes and astigmatism than patients who had variants categorized as mild. This corresponds to the outcomes of the studies previously mentioned, in which variants categorized as severe were more likely to lead to an early onset of ESKD and ocular changes (Gross et al. 2002; Savige et al. 2019). A lenticonus occurs more frequently in patients with large COL4A5 deletions or variants that alter the reading frame (Jais et al. 2000).

The EPA trial did not find lenticonus and therefore no connection to a variant could be observed. However, the EPA trial showed that patients with macular thinning, macular pigment, and a vitreous body degeneration tended to have variants categorized as medium or severe.

4.2.10 Limitations of the study

The patients in the EPA trial were examined in various centers by different ophthalmologists which may not have had the same knowledge level of AS.

Medical reports were documented differently. Some reports listed the examination methods completely and described specifics such as the ocular fundus details and anterior segment findings. Other reports answered the provided worksheet checkmarks such as lenticonus anterior and macular pigment but did not include specific examination methods. Symptom information such as macular thinning or retinopathy was not requested in the worksheet. Therefore, the ophthalmologists may have not been aware that Alport patients can exhibit these lesions.

A long-term evolvement of the ocular changes could not be observed because most patients were only examined once, not every three years as it was planned. The examination methods and the patient data varied between the different studies. This is mainly related to different patient ages, patient numbers, ocular parameters, and different Alport stages.

4.2.11 Discussion conclusion

The pediatric Alport patients of the EPA trial showed ocular changes. Hyperopia and astigmatism were symptoms documented in the medical reports of the children. The prevalence of astigmatism in these Alport children was high compared to studies of astigmatism in the healthy population. Findings which were related specifically to AS were macular pigment, macular thinning, and vitreous body degeneration. Next to the EPA trial the cited studies also observed that these changes are characteristic for AS.

The EPA trial did not find lenticonus or retinopathy and showed lower percentages of macular thinning and macular pigment than the in the discussion cited studies. A reason for this could be that examinations which were done in the EPA trial were not precise enough to find the ocular changes. Table 12 gives an overview of the examination methods documented in the EPA trial in comparison with the examination methods documented in the cited studies. The studies included examinations such as OCT, fundus photography, electro and oculogram, fundus autofluorescence, autofluorescence imaging, retinoscopy for the oil-droplet sign, and retinal photography. With a broader spectrum of examination methods, it is possible that the cited studies were able to detect more ocular changes.

Table 12 Comparison of examination methods in the EPA trial and cited studies

Ocular changes	Examination methods in the EPA trial	Examination methods in cited studies
Macular thinning	OCT, fundus photography	OCT, fundus photography
Macular pigment	Fundoscopy	Ophthalmoscopy, fundoscopy, electro and oculogram, fluorescein angiography, slit and stereo lamp, fundus autofluorescence, OCT
Further macular findings: bull's eye and vitelliform maculopathy	N/A	Fluorescein angiography, OCT, autofluorescence imaging
Vitreous body degeneration	Fundoscopy and anterior segment exam	Fundoscopy and anterior segment exam
Lenticonus	N/A	Retinoscopy: oil-droplet sign
Retinopathy	N/A	Retinal photography, dilation of pupils, fundus photography

A long-term evolvement of the ocular changes could not be evaluated, see 4.2.10. At the time of the diagnosis, the EPA children with the Alport specific ocular changes were between seven and ten years old with the exception of one child who was 20 years old. Most of the in the discussion cited studies examined children as well as adults. EPA patients with the specific Alport changes exhibited a variant of the kidney disease categorized as medium or severe and were in Alport stages I or II. In contrast, patients of the cited studies had already reached ESKD. They were on dialysis or had received a renal transplant.

The Alport patients of the EPA trial were sent to the ophthalmologists in the context of a regular ocular examination. Therefore, elaborate tests were not expected to be performed. This shows that a regular ocular screening is not enough to detect possible Alport specific ocular lesions. More precise examination methods such as OCT, fluorescence angiography, and retinal photography are needed in order to detect ocular changes in Alport patients.

4.3 Outlook

Ocular involvement is likely to be overlooked in Alport patients when ophthalmologists are unaware of the specific changes.

To guide ophthalmologists to diagnose ocular changes in pediatric Alport patients an Alport eye pass can be included in the parents' child booklet, see Appendix 2 and 3.

When diagnosing a child with AS, the pediatric nephrologist should inform the parents of possible ocular changes. The pediatric nephrologist would hand out the Alport eye pass to the parents which they would present to an ophthalmologist for further evaluation of an ocular involvement.

The Alport eye pass includes the contact information, diagnosis and medication of the child. Possible ocular changes of AS such as anterior lenticonus, retinopathy, macular thinning, macular pigment, vitreous body opacity, and astigmatism are listed in the Alport eye pass. To ensure continuous ocular observations, it suggests that examinations should begin at age six and should be followed up every three years depending on the ocular report. The Alport eye pass offers a table where the ophthalmologist can document the performed examination methods and results.

Further studies including ocular and renal manifestations are recommended to continue the knowledge increase of AS. It is advisable to conduct an additional study with more Alport patients where specific directions for precise diagnostic methods and ocular changes are given. The Alport eye pass can help in this study.

A close cooperation between the pediatric nephrologist, the parents and the ophthalmologist is key to recognize, diagnose, and to treat ocular changes.

5 Summary

The objective of this dissertation was to characterize the ocular changes in pediatric Alport patients of the EARLY PRO-TECT Alport trial. The EARLY PRO-TECT Alport trial examined the safety and efficacy of angiotensin converting enzyme inhibitors as an early therapeutic option for pediatric Alport patients. Alport syndrome leads to renal insufficiency eventually ending in end stage kidney disease. Untreated patients get renal insufficiency early, requiring kidney replacement methods such as dialysis at the age of about 20 or a renal transplant. Other common symptoms of Alport Syndrome involve auricular and ocular changes.

Medical reports and worksheets were examined for ocular parameters such as astigmatism, refractive power, and Alport specific changes. The kidney parameters Alport stages and gene variant were included in the data collection to observe the relation to ocular changes. A statistical evaluation supported the processing of data to relate them to the patient collective.

The results of the EARLY PRO-TECT Alport trial evaluation showed hyperopia and astigmatism in most patients. Macular thinning, macular pigment, and vitreous body degeneration were found in 11% ($n = 5$). These patients were between seven and ten years old, except one patient who was 20 years old. They were in Alport stages I or II and had a gene variant with a medium or severe course of the kidney disease.

Other studies observed higher percentages of the Alport specific changes macular thinning, macular pigment, and vitreous body degeneration than the EARLY PRO-TECT Alport trial. In addition, the studies found lenticonus and retinopathy. The literature mainly focused on adults while the EARLY PRO-TECT Alport trial examined a pediatric population. The EARLY PRO-TECT Alport trial and the other studies differed in the examination methods and data such as patient age, patient numbers, ocular parameters, and Alport stages.

The results of the EARLY PRO-TECT Alport trial showed that it is beneficial to examine children more specifically and that there should be minimum requirements to examine children more precisely using examination methods such as optical coherence tomography, fluorescence angiography, and retinal photography. A routine ocular examination is not seen to be sufficient to detect Alport specific ocular changes.

Therefore, as an instruction to the ophthalmologist, an Alport eye pass was developed to perform a more precise examination.

6 Appendix

6.1 Worksheet



EARLY PRO-TECT Alport: Worksheet für den Augenarzt

Pat.-ID: 93 _ _

1. Datum der Untersuchung: tt.mm.jjjj

2. Lenticonus anterior: Ja Nein

links rechts

3. Katarakt: Ja Nein

links rechts

4. Maculaflecken: Ja Nein

links rechts

5. Weitere Augenbefunde: _____

Arzt: _____

Signatur: _____

Vielen Dank für Ihre Unterstützung!

6.2 Alport eye pass

Page 2

To be documented by the doctor

Age	Date	SL	OCT	RP	FS	Vision	Report
6							
9							
12							
15							
18							
21							

Abbreviations:
 SL: Slit-lamp RP: Retinal photography FS: Fundoscopy ; oil-droplet sign

Page 1

Alport eye pass

Patient: name/ date of birth _____
 Doctor: _____
 Address _____
 Address _____
 Tel. _____
 Tel. _____

Diagnosis: _____
 Medication: _____

- Possible eye changes:
- Lenticonus (anterior)
 - Retinopathy
 - Macular thinning
 - Macular pigment
 - Vitreous body opacity
 - Astigmatism

Ophthalmic examination at age six, then every three years, depending on the findings

Seite 2

Seite 1

Alport Augenpass

Patient: Name/ Geburtsdatum _____

Arzt: _____

Anschrift _____

Anschrift _____

Tel. _____

Tel. _____

Diagnose: _____

Medikamente: _____

Mögliche Augenveränderungen:

- Lenticonus (anterior)
- Retinopathie
- Makulaverdünnung
- Makulapigment
- Glaskörpertrübung
- Astigmatismus

Augenärztliche Kontrolle sollte ab 6 Jahren und je nach Befund nachfolgend alle 3 Jahre erfolgen.

Durch den Arzt einzutragen

LJ	Datum	SL	OCT	NF	FS	Visus	Befund
6							
9							
12							
15							
18							
21							

Abkürzungen:

- LJ: Lebensjahr
- NF: Netzhaut-Fotographie
- SL: Spaltlampe
- FS: Funduskopie ; Öl Tröpfchen Zeichen

7 References

- Ahmed F, Kamae KK, Jones DJ, DeAngelis MM, Hageman GS, Gregory MC, Bernstein PS (2013): Temporal macular thinning associated with X-linked Alport syndrome. *JAMA Ophthalmol* 131, 777–782
- Alport AC (1927): Hereditary familial congenital haemorrhagic nephritis. *Br Med J* 1, 504–506
- Atkin CL, Gregory MC, Border WA (1988): Alport syndrome. *Diseases of the kidney* 4, 617–641
- Bahar I, Vinker S, Livny E, Kaiserman I (2010): Possible association between keratoconus and renal diseases. *J Clin Exp Ophthalmol* 1, 1000112
- Bemme: „Ocular changes in Alport Syndrome within The 2015 International Workshop for Alport Syndrome, Göttingen, 25.09.-27.09.2015“
- Boutaud A, Borza DB, Bondar O, Gunwar S, Netzer KO, Singh N, Ninomiya Y, Sado Y, Noelken ME, Hudson BG (2000): Type IV Collagen of the Glomerular Basement Membrane Evidence that the chain specificity of network assembly is encoded by the noncollagenous NC1 domains. *J Biol Chem* 275, 30716–30724
- Braun J, Wiegand D (Hrsg.): *Basislehrbuch Innere Medizin*. 6. Edition; Elsevier/Urban & Fischer, München 2018
- Brenner BM, Cooper ME, de Zeeuw D, Keane WF, Mitch WE, Parving HH, Remuzzi G, Snapinn SM, Zhang Z, Shahinfar S (2001): Effects of losartan on renal and cardiovascular outcomes in patients with type 2 diabetes and nephropathy. *N Engl J Med* 345, 861–869
- Chen Y, Colville D, Ierino F, Symons A, Savige J (2018): Temporal retinal thinning and the diagnosis of Alport syndrome and thin basement membrane nephropathy. *Ophthalmic Genet* 39, 208–214
- Chin MP, Bakris GL, Block GA, Chertow GM, Goldsberry A, Inker LA, Heerspink HJL, O’Grady M, Pergola PE, Wanner C et al. (2018): Bardoxolone methyl improves kidney function in patients with chronic kidney disease stage 4 and type 2 diabetes: Post-Hoc analyses from bardoxolone methyl evaluation in patients with chronic kidney disease and type 2 diabetes study. *Am J Nephrol* 47, 40-47
- Cho IH, Kim HD, Jung SJ, Park TK (2017): En face optical coherence tomography findings in a case of Alport syndrome. *Indian J Ophthalmol* 65, 877–879
- Colville DJ, Savige J, Morfis M, Ellis J, Kerr P, Agar J, Fasset R (1997): Ocular manifestations of autosomal recessive Alport syndrome. *Ophthalmic Genet* 18, 119–128

- Colville DJ, Savige J (1997): A review of the ocular manifestations. *Ophthalmic Genet* 18, 161–173
- Daugirdas JT, Blake PG, Ing TS (Hrsg.): *Handbook of dialysis*. 4. Edition; Lippincott Williams & Wilkins, Philadelphia 2012
- Davidson JA (2019): SGLT2 inhibitors in patients with type 2 diabetes and renal disease: overview of current evidence. *Postgrad Med* 131, 251–260
- de Zeeuw D, Akizawa T, Audhya P, Bakris GL, Chin M, Christ-Schmidt H, Goldsberry A, Houser M, Krauth M, Lambers Heerspink HJ et al. (2013): Bardoxolone methyl in type 2 diabetes and stage 4 chronic kidney disease. *N Engl J Med* 369, 2492–2503
- Fawzi AA, Lee NG, Elliott D, Song J, Stewart JM (2009): Retinal findings in patients with Alport Syndrome: expanding the clinical spectrum. *Br J Ophthalmol* 93, 1606–1611
- Fledelius HC, Stubgaard M (1986): Changes in refraction and corneal curvature during growth and adult life. *Acta Ophthalmol (Copenh)* 64, 487–491
- Fozailoff A, Tarczy-Hornoch K, Cotter S, Wen G, Lin J, Borchert M, Azen S, Varma R (2011): Prevalence of astigmatism in 6- to 72-Month-Old African American and Hispanic children: The multi-ethnic pediatric eye disease study. *Ophthalmology* 118, 284–293
- Frei U, Schober-Halstenberg HJ (2008): *Nierenersatztherapie in Deutschland*. QuaSi Jahresbericht 2008, Berlin
- Fulton AB, Hansen RM, Petersen RA (1982): The relation of myopia and astigmatism in developing eyes. *Ophthalmology* 89, 298–302
- Funk SD, Lin M-H, Miner JH (2018): Alport syndrome and Pierson syndrome: diseases of the glomerular basement membrane. *Matrix Biol J Int Soc Matrix Biol* 71–72, 250–261
- Gehrs K, Pollock S, Zilkha G (1995): Clinical features and pathogenesis of Alport retinopathy. *Retina Phila Pa* 15, 305–311
- Giordano L, Friedman DS, Repka MX, Katz J, Ibrionke J, Hawes P, Tielsch JM (2009): Prevalence of refractive error among preschool children in an urban population: the Baltimore pediatric eye disease study. *Ophthalmology* 116, 739-746.e4
- Gomez IG, MacKenna DA, Johnson BG, Kaimal V, Roach AM, Ren S, Nakagawa N, Xin C, Newitt R, Pandya S, et al. (2015): Anti-microRNA-21 oligonucleotides prevent Alport nephropathy progression by stimulating metabolic pathways. *J Clin Invest* 125, 141–156
- Govan JA (1983): Ocular manifestations of Alport's syndrome: a hereditary disorder of basement membranes? *Br J Ophthalmol* 67, 493–503

- Groopman EE, Marasa M, Cameron-Christie S, Petrovski S, Aggarwal VS, Milo-Rasouly H, Li Y, Zhang J, Nestor J, Krithivasan P, et al. (2018): Diagnostic utility of exome sequencing for kidney disease. *N Engl J Med* 380, 142–151
- Gross O (2004): Alport syndrom und familiäre benigne Hämaturie. *Nieren und Hochdruckkrankheiten* 7, 348–356
- Gross O (2017): Leben mit Alport-Syndrom. *Nephrol* 12, 257–263
- Gross O, Weber M (2005): Von der Molekulargenetik des Alport-Syndroms zu Prinzipien der Organprotektion bei chronischen Nierenerkrankungen. *Med Klin* 100, 826–831
- Gross O, Kashtan CE (2009): Treatment of Alport syndrome: beyond animal models. *Kidney Int* 76, 599–603
- Gross O, Rascher W (2019): Nephroprotektive Therapie am Beispiel des Alport-Syndroms. *Monatsschr Kinderheilkd* 167, 522–529
- Gross O, Netzer K, Lambrecht R, Seibold S, Weber M (2002): Meta-analysis of genotype–phenotype correlation in X-linked Alport syndrome: impact on clinical counselling. *Nephrol Dial Transplant* 17, 1218–1227
- Gross O, Beirowski B, Koepke M-L, Kuck J, Reiner M, Addicks K, Smyth N, Schulze-Lohoff E, Weber M (2003): Preemptive ramipril therapy delays renal failure and reduces renal fibrosis in COL4A3-knockout mice with Alport syndrome¹¹See Editorial by Abbate and Remuzzi, p. 764. *Kidney Int* 63, 438–446
- Gross O, Licht C, Anders HJ, Hoppe B, Beck B, Tönshoff B, Höcker B, Wygoda S, Ehrich JHH, Pape L, et al. (2012a): Early angiotensin-converting enzyme inhibition in Alport syndrome delays renal failure and improves life expectancy. *Kidney Int* 81, 494–501
- Gross O, Friede T, Hilgers R, Görlitz A, Gavénis K, Ahmed R, Dürr U (2012b): Safety and efficacy of the ACE-inhibitor ramipril in Alport syndrome: The double-blind, randomized, placebo-controlled, multicenter phase III EARLY PRO-TECT Alport trial in pediatric patients. *ISRN Pediatr* 2012, 10.5402/2012/436046
- Gross O, Perin L, Deltas C (2014): Alport syndrome from bench to bedside: the potential of current treatment beyond RAAS blockade and the horizon of future therapies. *Nephrol Dial Transplant* 29, 10.1093/ndt/gfu028
- Gross O, Kashtan CE, Rheault MN, Flinter F, Savige J, Miner JH, Torra R, Ars E, Deltas C, Savva I, et al. (2017): Advances and unmet needs in genetic, basic and clinical science in Alport syndrome: report from the 2015 international workshop on Alport syndrome. *Nephrol Dial Transplant* 32, 916–924

- Gross O, Tönshoff B, Weber LT, Pape L, Latta K, Fehrenbach H, Lange-Sperandio B, Zappel H, Hoyer P, Staude H, et al. (2020): A multicenter, randomized, placebo-controlled, double-blind phase 3 trial with open-arm comparison indicates safety and efficacy of nephroprotective therapy with ramipril in children with Alport's syndrome. *Kidney Int*
- Grünfeld JP, Joly D (1997): [Hereditary kidney diseases in adults]. *Rev Prat* 47, 1566–1569
- Grünfeld JP (2000): Contemporary diagnostic approach in Alport's syndrome. *Ren Fail* 22, 759–763
- Gubler M, Levy M, Broyer M, Naizot C, Gonzales G, Perrin D, Habib R (1981): Alport's syndrome: A report of 58 cases and a review of the literature. *Am J Med* 70, 493–505
- Gupta V, Jamil M, Luthra S, Puthalath AS (2019): Alport syndrome with bilateral simultaneous anterior and posterior lenticonus with severe temporal macular thinning. *BMJ Case Rep* 12, 10.1136/bcr-2019-229554
- Gwiazda J, Scheiman M, Mohindra I, Held R (1984): Astigmatism in children: changes in axis and amount from birth to six years. *Invest Ophthalmol Vis Sci* 25, 88–92
- Gwiazda J, Grice K, Held R, McLellan J, Thorn F (2000): Astigmatism and the development of myopia in children. *Vision Res* 40, 1019–1026
- Harvey SJ, Mount R, Sado Y, Naito I, Ninomiya Y, Harrison R, Jefferson B, Jacobs R, Thorner PS (2001): The inner ear of dogs with X-linked nephritis provides clues to the pathogenesis of hearing loss in X-linked Alport syndrome. *Am J Pathol* 159, 1097–1104
- Heidet L, Gubler M-C (2009): The renal lesions of Alport syndrome. *J Am Soc Nephrol* 20, 1210–1215
- Hentati N, Sellami D, Makni K, Kharrat M, Hachicha J, Hammadi A, Feki J (2008): Ocular findings in Alport syndrome: 32 case studies. *J Fr Ophtalmol* 31, 597–604
- Hess K, Pfau M, Wintergerst MWM, Loeffler KU, Holz FG, Herrmann P (2020): Phenotypic spectrum of the foveal configuration and foveal avascular zone in patients with Alport syndrome. *Invest Ophthalmol Vis Sci* 61, 5–5
- Hiramatsu M (2007): How to improve survival in geriatric peritoneal dialysis patients. *Perit Dial Int* 27, 185–189
- Hirsch M (1963): Changes in astigmatism during the first eight years of school - an interim report from the Ojai longitudinal study. *Am J Optom Arch Am Acad Optom* 40, 127–132
- Hudson BG, Tryggvason K, Sundaramoorthy M, Neilson EG (2003): Alport's syndrome, Goodpasture's syndrome, and type IV collagen. *N Engl J Med* 348, 2543–2556

- Jais JP, Knebelmann B, Giatras I, Marchi MD, Rizzoni G, Renieri A, Weber M, Gross O, Netzer K-O, Flinter F, et al. (2000): X-linked Alport syndrome: natural history in 195 families and genotype- phenotype correlations in males. *J Am Soc Nephrol* 11, 649–657
- Jais JP, Knebelmann B, Giatras I, De Marchi M, Rizzoni G, Renieri A, Weber M, Gross O, Netzer K-O, Flinter F, et al. (2003): X-linked Alport syndrome: natural history and genotype-phenotype correlations in girls and women belonging to 195 families: a „European community Alport syndrome concerted action“ study. *J Am Soc Nephrol JASN* 14, 2603–2610
- Kalluri R, Gattone VH, Hudson BG (1998): Identification and localization of type IV collagen chains in the inner ear cochlea. *Connect Tissue Res* 37, 143–150
- Kashtan CE (1999): Alport syndrome: an inherited disorder of renal, ocular, and cochlear basement membranes. *Medicine (Baltimore)* 78, 338–360
- Kashtan CE (2000): Alport syndrome: abnormalities of type IV collagen genes and proteins. *Ren Fail* 22, 737–749
- Kashtan CE (2001): Collagen IV-related nephropathies (Alport syndrome and thin basement membrane nephropathy). *Am J Kidney Dis* 26, 1–25
- Kashtan CE (2003): Alport syndrome and thin basement membrane nephropathy: diseases arising from mutations in type IV collagen. *Saudi J Kidney Dis Transplant* 14, 276–289
- Kashtan CE (2004): Familial hematuria due to type IV collagen mutations: Alport syndrome and thin basement membrane nephropathy. *Curr Opin Pediatr* 16, 177–181
- Kashtan CE (2009): Familial hematuria. *Pediatr Nephrol* 24, 1951–1958
- Kashtan CE (2018): Renal transplantation in patients with Alport syndrome: patient selection, outcomes, and donor evaluation. *Int J Nephrol Renov Dis* 11, 267–270
- Kashtan CE, Michael AF (1996): Alport syndrome. *Kidney Int* 50, 1445–1463
- Kashtan CE, Ding J, Gregory M, Gross O, Heidet L, Knebelmann B, Rheault M, Licht C (2013): Clinical practice recommendations for the treatment of Alport syndrome: a statement of the Alport Syndrome Research Collaborative. *Pediatr Nephrol Berl Ger* 28, 5–11
- Kim SL, Han DC, Lee HB (2000): Lovastatin inhibits transforming growth factor- β 1 expression in diabetic rat glomeruli and cultured rat mesangial cells. *J Am Soc Nephrol* 11, 80-87

- Koepke M-L, Weber M, Schulze-Lohoff E, Beirowski B, Segerer S, Gross O (2007): Nephroprotective effect of the HMG-CoA-reductase inhibitor cerivastatin in a mouse model of progressive renal fibrosis in Alport syndrome. *Nephrol Dial Transplant Off Publ Eur Dial Transpl Assoc - Eur Ren Assoc* 22, 1062–1069
- Kruegel J, Rubel D, Gross O (2013): Alport syndrome—insights from basic and clinical research. *Nat Rev Nephrol* 9, 170–178
- Lang G: *Augenheilkunde*. 5. Edition; Thieme, Stuttgart 2014
- Lemmink HH, Schröder CH, Monnens LAH, Smeets HJM (1997): The clinical spectrum of type IV collagen mutations. *Hum Mutat* 9, 477–499
- Levy M, Feingold J (2000): Estimating prevalence in single-gene kidney diseases progressing to renal failure. *Kidney Int* 58, 925–943
- Mallett A, Tang W, Clayton PA, Stevenson S, McDonald SP, Hawley CM, Badve SV, Boudville N, Brown FG, Campbell SB, Johnson DW (2014): End-stage kidney disease due to Alport syndrome: outcomes in 296 consecutive Australia and New Zealand dialysis and transplant registry cases. *Nephrol Dial Transplant* 29, 2277–2286
- Mohindra I, Held R (Hrsg.): *Third international conference on myopia Copenhagen, August 24-27, 1980*. 28. Edition; Springer Netherlands, Dordrecht 1980
- Moshirfar M, Skanchy DF, Gomez AT, Ronquillo YC, Buckner B, Hoopes PC (2019): keratoconus in a patient with Alport syndrome: A case report. *World J Clin Cases* 7, 3012–3017
- Multi-Ethnic Pediatric Eye Disease Study Group (2010): Prevalence of myopia and hyperopia in 6- to 72-month-old African American and Hispanic children: the multi-ethnic pediatric eye disease study. *Ophthalmology* 117, 10.1016/j.optha.2009.06.009
- Mutti DO, Mitchell GL, Jones LA, Friedman NE, Frane SL, Lin WK, Moeschberger ML, Zadnik K (2004): Refractive astigmatism and the toricity of ocular components in human infants. *Optom Vis Sci* 81, 753–761
- Nespoux J, Vallon V (2018): SGLT2 inhibition and kidney protection. *Clin Sci Lond Engl 1979* 132, 1329–1339
- Netzer K-O, Pullig O, Frei U, Zhou J, Tryggvason K, Weber M (1993): COL4A5 splice site mutation and $\alpha 5(\text{IV})$ collagen mRNA in Alport syndrome. *Kidney Int* 43, 486–492
- Nozu K, Nakanishi K, Abe Y, Udagawa T, Okada S, Okamoto T, Kaito H, Kanemoto K, Kobayashi A, Tanaka E, et al. (2019): A review of clinical characteristics and genetic backgrounds in Alport syndrome. *Clin Exp Nephrol* 23, 158–168
- Ohkubo S, Takeda H, Higashide T, Ito M, Sakurai M, Shirao Y, Yanagida T, Oda Y, Sado

- Y (2003): Immunohistochemical and molecular genetic evidence for type IV collagen $\alpha 5$ chain abnormality in the anterior lenticonus associated with Alport syndrome. *Arch Ophthalmol* 121, 846–850
- Ojaimi E, Rose KA, Morgan IG, Smith W, Martin FJ, Kifley A, Robaei D, Mitchell P (2005): Distribution of ocular biometric parameters and refraction in a population-based study of Australian children. *Invest Ophthalmol Vis Sci* 46, 2748–2754
- Overlack A (1996): ACE inhibitor induced cough and bronchospasm: incidence, mechanisms and management. *Drug Saf* 15, 72–78
- Perrin D, Jungers P, Grünfeld J, Delons S, Noël L, Zenatti C (1980): Perimacular changes in Alport's syndrome. *Clin Nephrol* 13, 163–167
- Phelan PJ, Rheault MN (2018): Hearing loss and renal syndromes. *Pediatr Nephrol Berl Ger* 33, 1671–1683
- Pirson Y (1999): Making the diagnosis of Alport's syndrome. *Kidney Int* 56, 760–775
- Pöschl E, Schlötzer-Schrehardt U, Brachvogel B, Saito K, Ninomiya Y, Mayer U (2004): Collagen IV is essential for basement membrane stability but dispensable for initiation of its assembly during early development. *Development* 131, 1619–1628
- Prajna NV: FAQs in Ophthalmology. 1. Edition; Jaypee Brothers Medical Publishers, India 2013
- Ravi Kant Bamotra M (2017): Simultaneous Bilateral Anterior and Posterior Lenticonus in Alport Syndrome. *J Clin Diagn Res JCDR* 11, 10.7860/JCDR/2017/25521.10369
- Read SA, Collins MJ, Carney LG (2007): A review of astigmatism and its possible genesis. *Clin Exp Optom* 90, 5–19
- Renieri A, Bruttini M, Galli L, Zanelli P, Neri T, Rossetti S, Turco A, Heiskari N, Zhou J, Gusmano R, et al. (1996): X-linked Alport syndrome: an SSCP-based mutation survey over all 51 exons of the COL4A5 gene. *Am J Hum Genet* 58, 1192–1204
- Rheault MN, Savige J, Randles MJ, Weinstock A, Stepney M, Turner AN, Parziale G, Gross O, Flinter FA, Miner JH, et al. (2019): The importance of clinician, patient and researcher collaborations in Alport syndrome. *Pediatr Nephrol* 5, 1–10
- Rüster C, Wolf G (2006): Renin-angiotensin-aldosterone system and progression of renal disease. *J Am Soc Nephrol* 17, 2985–2991
- Satterfield DS (1989): Prevalence and variation of astigmatism in a military population. *J Am Optom Assoc* 60, 14–18
- Savige J (2018): Alport syndrome: deducing the mode of inheritance from the presence of haematuria in family members. *Pediatr Nephrol* 35, 59–66

Savige J, Liu J, DeBuc DC, Handa JT, Hageman GS, Wang YY, Parkin JD, Vote B, Fassett R, Sarks S, Colville D (2010): Retinal basement membrane abnormalities and the retinopathy of Alport syndrome. *Invest Ophthalmol Vis Sci* 51, 1621–1627

Savige J, Gregory M, Gross O, Kashtan CE, Ding J, Flinter F (2013): Expert guidelines for the management of Alport syndrome and thin basement membrane nephropathy. *J Am Soc Nephrol* 24, 364–375

Savige J, Sheth S, Leys A, Nicholson A, Mack HG, Colville D (2015): Ocular features in Alport syndrome: pathogenesis and clinical significance. *Clin J Am Soc Nephrol CJASN* 10, 703–709

Savige J, Storey H, Il Cheong H, Gyung Kang H, Park E, Hilbert P, Persikov A, Torres-Fernandez C, Ars E, Torra R, et al. (2016): X-linked and autosomal recessive Alport syndrome: pathogenic variant features and further genotype-phenotype correlations. *PloS One* 11, 0161802

Savige J, Wang Y, Crawford A, Smith J, Symons A, Mack H, Nicholls K, Wilson D, Colville D (2017): Bull's eye and pigment maculopathy are further retinal manifestations of an abnormal Bruch's membrane in Alport syndrome. *Ophthalmic Genet* 38, 238–244

Savige J, Ariani F, Mari F, Bruttini M, Renieri A, Gross O, Deltas C, Flinter F, Ding J, Gale DP, et al. (2019): Expert consensus guidelines for the genetic diagnosis of Alport syndrome. *Pediatr Nephrol* 34, 1175–1189

Shaikh S, Garretson B, Williams GA (2003): Vitreoretinal degeneration complicated by retinal detachment in Alport Syndrome. *RETINA* 23, 119–120

Shaw EA, Colville D, Wang YY, Zhang KW, Dagher H, Fassett R, Guymer R, Savige J (2007): Characterization of the peripheral retinopathy in X-linked and autosomal recessive Alport syndrome. *Nephrol Dial Transplant* 22, 104–108

Sonarkhan S, Ramappa M, Chaurasia S, Mulay K (2014): Bilateral anterior lenticonus in a case of Alport syndrome: a clinical and histopathological correlation after successful clear lens extraction. *BMJ Case Rep* 2014, 10.1136/bcr-2013-202036

Štabuc-Šilih M, Ravnik-Glavač M, Glavač D, Hawlina M, Stražišar M (2009): Polymorphisms in COL4A3 and COL4A4 genes associated with keratoconus. *Mol Vis* 15, 2848–2860

Stock J, Kuenanz J, Glonke N, Gross O (2015): Potential of RAAS- blockade to halt renal disease in heterozygous carriers of Alport-mutations: a 4- year prospective study. *Nephrol Dial Transplant* 30, 10.1093/ndt/gfv175.49

- Strasser K, Hoefele J, Bergmann C, Büscher AK, Büscher R, Hoyer PF, Weber S (2012): COL4A5-associated X-linked Alport syndrome in a female patient with early inner ear deafness due to a mutation in MYH9. *Nephrol Dial Transplant Off Publ Eur Dial Transpl Assoc - Eur Ren Assoc* 27, 4236–4240
- Suranyi E, Nagy V, Berta A, Matyus J, Szalai E, Ujhelyi B, Meleg J, Damjanovich J (2019): Alport patients without classic ocular symptoms have smaller lens diameter. *Med Sci Monit Int Med J Exp Clin Res* 25, 2274–2277
- Tan R, Colville D, Wang YY, Rigby L, Savige J (2010): Alport retinopathy results from “severe” COL4A5 mutations and predicts early renal failure. *Clin J Am Soc Nephrol CJASN* 5, 34–38
- Thompson SM, Deady JP, Willshaw HE, White RHR (1987): Ocular signs in Alport’s syndrome. *Nature Publishing Group* 1, 146-153
- Torra R, Furlano M (2019): New therapeutic options for Alport syndrome. *Nephrol Dial Transplant* 34, 1272–1279
- Watson S, Bush JS: Alport Syndrome. StatPearls Publishing, Florida 2019
- Webb NJA, Shahinfar S, Wells TG, Massaad R, Gleim GW, Sisk CM, Lam C (2013): Losartan and enalapril are comparable in reducing proteinuria in children with Alport syndrome. *Pediatr Nephrol* 28, 737–743
- Weber M (1992): Basement membrane proteins. *Kidney Int* 41, 620–628
- Wester DC, Atkint CL, Gregory MC (1995): Alport syndrome: clinical update. *J Am Acad Audiol* 6, 73–79
- Wolf G, Ritz E (2005): Combination therapy with ACE inhibitors and angiotensin II receptor blockers to halt progression of chronic renal disease: Pathophysiology and indications. *Kidney Int* 67, 799–812
- Wolfram C, Höhn R, Kottler U, Wild P, Blettner M, Bühren J, Pfeiffer N, Mirshahi A (2014): Prevalence of refractive errors in the European adult population: the Gutenberg Health Study (GHS). *Br J Ophthalmol* 98, 857–861
- Wühl E, Mehls O, Schaefer F (2004): Antihypertensive and antiproteinuric efficacy of ramiprilin children with chronic renal failure. *Kidney Int* 66, 768–776
- Yamamura T, Nozu K, Fu XJ, Nozu Y, Ye MJ, Shono A, Yamanouchi S, Minamikawa S, Morisada N, Nakanishi K, et al. (2017): Natural history and genotype–phenotype correlation in female X-linked Alport syndrome. *Kidney Int Rep* 2, 850–855
- Ying G, Maguire MG, Cyert LA, Ciner E, Quinn GE, Kulp MT, Orel-Bixler D, Moore B (2014): Prevalence of vision disorders by racial and ethnic group among children participating in head start. *Ophthalmology* 121, 630–636

Zhang KW, Colville D, Tan R, Jones C, Alexander SI, Fletcher J, Savige J (2008): The use of ocular abnormalities to diagnose X-linked Alport syndrome in children. *Pediatr Nephrol* 23, 1245–1250

Acknowledgement

At first, I would like to thank my doctoral supervisor Prof. Dr. Oliver Gross for assigning me the topic of my thesis and for his excellent supervision. Thank you for planning, discussing, and correcting the work together, for the time, patience, and the many meetings.

I would like to offer my special thanks to my second supervisor Prof. Dr. Nicolas Feltgen, for his support, professional ophthalmic assessment, motivation, joy in this work, and ideas.

Thank you Jan Böckhaus, my supervisor, for discussing the most important steps with me and for your enthusiastic encouragement. Your literature suggestions, instructions, and the many helpful conversations and email exchanges have motivated me very much.

My grateful thanks are also extended to Mr. Sebastian Pfeiffer, a staff member of the Institute of Medical Statistics. Your support during the statistical analysis was very helpful and indispensable for the evaluation of the data.